

TRANSMISSIBLE VIRAL PROVENTRICULITIS AND STUNTING SYNDROME IN BROILER CHICKENS IN EGYPT: 1. ISOLATION AND CHARACTERIZATION OF VARIANT INFECTIOUS BURSAL DISEASE VIRUS (IBDV)

H.A. HUSSEIN *, A.M. ALY **, H. SULTAN *** and M. AL-SAFETY**

*Department of Virology, Faculty of Veterinary Medicine, Cairo University, Giza-Egypt, 12211.

**Central laboratory for evaluation of Veterinary Biologics, Abassia-Cairo, Egypt.

*** Department of poultry, Faculty of Veterinary Medicine, Tanta University, Egypt

Received: 22.6.2003.

Accepted: 30.6.2003.

SUMMARY

In the present study, 46 broiler chicken flocks (2 to 4 weeks of age and in farms located in four governorates were examined. They were affected with proventriculitis and stunting syndrome and were vaccinated with classical infectious bursal disease vaccines. Affected flocks generally showed stunting, reduced growth rate and uneven weight distribution. Necropsy of chicks revealed high incidence of increased size of the proventriculus. Transmission and isolation studies of causative agent were undertaken in one-day-old SPF chicks using homogenates from proventriculus collected from 5 flocks from El-Fayoum governorate. Gross and histological changes were observed in inoculated chicks for 2 weeks. In addition, sera collected from inoculated chicks at the

end of the observation period were tested by ELISA for infectious bursal disease virus (IBDV), infectious bronchitis virus (IBV), *Mycoplasma gallisepticum* (MG), *Mycoplasma synoviae* (MS), chicken anemia virus (CAV), avian leucosis virus (ALV), avian leucosis virus subgroup-J (ALV-J), reticuloendotheliosis virus (REV), Newcastle disease virus (NDV), avian rhinotracheitis virus (ARTV) and Reo virus. Proventricular homogenates were prepared from the inoculated chicks and inoculated for 2 more passages in SPF chicks. The results revealed that the inoculum was infectious and transmissible as judged by the induction of proventriculitis throughout the three passages in SPF chicks. Signs of anemia and immunosuppression (liver, spleen, bursa) were observed in necropsied chicks. Infectious bursal disease virus (IBDV) antibodies were detected in

sera of inoculated chicks. Histopathological examination of organs (proventriculus, bursa, spleen, kidney and liver) from the inoculated SPF chicks revealed pathological changes described in details. IBDV was detected in bursae collected from inoculated chicks throughout the three passages using antigen capture ELISA, based on the use of a common VP2 epitope of IBDV. Antigenic typing of the isolated virus in bursae collected from the third passage using a panel of 3 monoclonal antibodies directed against VP2 epitopes of IBDV revealed that the isolated virus was related to Delaware (E/Del) variant strain of IBDV. The isolated IBDV was inoculated into nonvaccinated commercial broiler chicks (6-8 days of age) that had maternally-derived IBDV antibodies (from breeders vaccinated with classical IBDV). The virus was detected in the bursa at 72 hours PI by ELISA and electron microscope confirming the persistence of the variant IBDV in the chicks despite the presence of IBDV classical antibodies. The present study reports for the first time the association of IBDV with stunting syndrome and proventriculitis in broilers in Egypt.

Key words: IBDV; Variant, Proventriculitis, runtting syndrome, Immunosuppression, Antigen-capture.

INTRODUCTION

Proventriculitis is a serious and ongoing problem

causing significant economic losses in broiler chicken industry (Reece, 2001). Proventriculitis has been associated with so called feed passage or malabsorption syndrome and poor broiler performance. For years, proventriculitis in broiler chicken occurred occasionally (Kouwenhoven et al., 1986; MartLand, 1989). Several etiological agents including infectious {reovirus, adenovirus, avian leucosis virus subgroup J (ALV-J), reticuloendotheliosis virus (REV), infectious bronchitis virus (IBV), Marek's disease virus (MDV), recently infectious bursal disease virus (IBDV)} and nutritional (mycotoxines and biogenic amines) have been described (Goodwin et al., 1996; Guy and Barnes, 2003). In the recent years, scoping on the infectious causes of immunodepression and transmissible proventriculitis in Australlia indicated the implication of avian entero-like virus, avian adeno group I, chicken anemia virus (CAV), ALV-J and IBDV (Reece, 2001).

However, in the USA, variant strains of IBDV have been recently proposed as the possible etiology of proventriculitis (Cookson, 2001; Huff et al., 2001 and Giambrone, 2002). In Egypt, the proventriculitis has been recently observed in commercial broilers in association with stunting syndrome and poor performance of such flocks. The problem is ongoing in different countries causing significant economic losses and the authors have recently examined 46 flocks located in several governorates, all were vaccinated against IBD and showed uneven growth and proventricu-

litis. The purpose of the present study is to investigate, isolate and characterize the possible cause(s) of infectious proventriculitis and stunting syndrome observed recently in broiler flocks in Egypt.

MATERIAL AND METHODS

Field samples

Forty six broiler chicken flocks ranging in age between 10 days to 4 weeks on farms located in Alexandria, Kaliobia, El-Sharkia and El-Fayoum Governorates were generally characterized by poor feed conversion, reduced growth rate, and uneven weight distribution. All flocks revealed increased size of proventriculus (proventriculitis).

The proventriculus wall was thick with white lobular pattern. Some proventricular glands were distended with viscous white material. The outer surface of the proventriculus was mottled and had white plaques. The clinical and gross findings were generally similar in the examined flocks. Proventriculus was collected from all affected flocks and used as the principal source of the samples in the present study. Pooled homogenates from proventriculus collected from 5 flocks representing El-Fayoum governorate were used in the transmission and isolation studies (those samples were chosen due to the previous history of IBDV outbreaks). The homogenates were prepared (10% in PBS) with addition of antibiotics before inoculation in SPF chicks.

Transmission and isolation of causative agents

A group of 25, one day-old SPF chicks were inoculated with the pooled proventricular homogenate intraocularly and orally (0.2 ml/chick). The chicks were observed for two weeks. At 2, 4, 5, 8, 10, 13 and 15 days post inoculation, three chicks were necropsized. Samples from proventriculus, liver, spleen, bursa of Fabricius and kidney were collected in neutral formalin for histopathology. Sera were collected from the inoculated chicks after 1 and 2 weeks for serological examination by ELISA. A second group of 10 non-inoculated chicks were served as controls.

Histopathology

Formalin-fixed tissues were processed in the usual way and paraffin sections (4-6 micron thickness) were prepared and stained with hematoxylin and eosin (Bancroft, 1996).

Serology

Sera collected from the remaining inoculated SPF chicks at 2 weeks post inoculation (PI) in the first passage were tested by ELISA for the presence of antibodies against the following agents: IBDV, IBV, MG, MS, CAV, ALV, ALV-J, REV, NDV, ARTV and Reo virus. Commercial ELISA kits were from IDEXX, SYNBIOTICS, and BIO-CHECK companies. Samples dilution, test procedure, validity and interpretations of the employed assays were carried out according to the manufacturer instructions. Sera collected from inoculated

SPF chicks at 1 and 2 weeks PI in the second and third passages were tested for IBDV (BD+ ELISA kit, SYNBIOTICS).

Isolation, propagation and characterization of the causative agent in SPF chicks

Proventricular homogenates prepared from the inoculated SPF chicks of the first passage at 1-4 days PI were used for two further passages in one day-old SPF chicks for propagation of the causative agent (s). Bursa, proventriculus, spleen, liver and kidney were collected in each passage after inoculation of the proventricular homogenate. Bursa was examined 72 hours PI for the presence of IBDV by antigen capture ELISA test kit Pro-flock (Synbiotics, Europe, Lyon, France). The kit contains the Mab # 8 which is used for the initial screening of bursa for the presence of IBDV strains, both types classical and variants.

The test procedure and interpretation were carried out according to the manufacturer instructions. Control bursae from non-inoculated SPF chicks were also included in the test. In a trial to detect the virus in proventriculus, proventricular homogenate 6-8 days PI was also tested in the IBDV antigen capture ELISA test kit.

Antigenic typing of the isolated virus

The isolated IBDV was antigenically typed using three more monoclonal antibodies included in an antigen capture ELISA test kit (Synbiotics, Europe, Lyon, France). The isolated virus was

typed first using the Mab B 69 that reacted with all the classical strains of IBDV and then tested with Mabs B 63 and # 10. IBDV that did not react with Mab B 69 was considered as variants (Snyder et al., 1994). The isolated virus was sub-typed according to its reactivity pattern with the utilized Mabs according to the manufacturer interpretations enclosed with the kit.

Inoculation of the isolated virus in non-vaccinated commercial broiler chicks

A pool of bursal and proventricular homogenates (collected from SPF chicks 1-4 days PI with the isolated virus) prepared as mentioned before was inoculated intraocularly and orally (0.2 ml/chick) in 6- 8 days-old commercial non-vaccinated broiler chicks that had IBDV maternal antibodies with a mean of 6578 ELISA titer (Commercial kit, Synbiotics, Europe, Lyon, France). After 72 hours PI, bursa was collected from the inoculated chicks and IBDV was detected using antigen capture ELISA and electron microscope. Electron microscopic examination was conducted at the vaccine and serum laboratories, Ministry of Health, Agouza, Cairo, Egypt. Also, typing of the detected IBDV in the collected bursae was carried out using antigen capture ELISA test kit as mentioned above.

RESULTS

Transmission of the infectious agent

Proventricular homogenates inoculated orally and

ocularly for the three passages into 1-day-old chicks induced reduction in growth rate compared to controls but no marked clinical signs except mild depression of some chicks. Gross lesions included marked increase in size of proventriculus which started at 8 days PI, and chicks necropsized at 2 weeks PI revealed distended proventriculus with dilated glands. There was mortality recorded PI in the first and second passages (Table 1). However, no mortalities have been recorded in third passage. All inoculated chicks showed atrophy of spleen, bursa and sign of anemia in liver. The proventricular ho-

mogenates were infectious as judged by the occurrence of proventricular lesions in the inoculated SPF chicks throughout the three passages. The proventricular homogenates were the only source of inoculum at each passage. The incidence of the lesions in proventriculus, sign of anaemia and atrophy in lymphoid organs induced by the inoculum was high in the three passages in SPF chicks.

Histopathological findings:

Proventriculus

The lining mucosal epithelium of the proventriculus was destructed whereas the underling lamina

Table (1): Mortalities recorded after inoculation of the proventricular homogenates in one- day-old SPF chicks in the first and second passages

Days post inoculation	Number of dead birds	
	First passage	Second passage
2	3	2
3	-	1
4	-	2
5	4	-
6	1	-
7	-	2
8	2	1
9	1	1
10	-	-
11	1	-
12	-	-
13	1	-
14	-	-
15	-	-
Total mortalities	13/25 (52%)	9/25 (36%)

propria showed fibrosis with inflammatory cell infiltration and necrosis in the glandular structure 2 days PI (Plate 1 A). By day 4 PI, necrosis in the glandular structure with oedema in the interstitial connective tissue stroma was seen (Plate 1 B) and associated with extravasation in the red blood cells in the muscular layer at 5 days PI (Plate 1 C). Marked massive number of mononuclear leucocytic inflammatory cell infiltration in the lamina propria of the muscular layer surrounded the affected area in the gland was observed at 8 days PI (Plate 1D). The marked inflammatory cell infiltration observed in the glandular structure as well as the stromal connective tissue either diffuse or in focal (Plate 2 A). At 13 days PI, necrosis was noticed in the glandular structure while the muscle layer was hyalinized (Plate 2 B). Oedema with focal inflammatory cells infiltration (Plate 2 C) and severe hyperemic blood capillaries of the plicae were observed in the lamina propria of the muscle layer at 15 days PI (Plate 2 D).

Spleen

The white pulps showed depletion of the lymphoid cells and ischemia of the red pulps at 2 days PI (Plate 3 A). Thickening of the splenic capsule was seen 4 days PI (Plate 3 B). By day 10 PI, depletion and necrobiotic changes were seen in the lymphoid cells of the white pulps (Plate 3 C and D).

Bursa of Fabricius

There was marked depletion in the lymphoid follicles associated with fibrosis after 2 to 4 days PI (Plate 4 A). Fibrosis inbetween the depleted follicles has progressed by 5 and 8 days PI. There was hyperplasia in the covering lining epithelium associated with the depletion in the follicles at 10 days PI (Plate 4 B). Focal inflammatory cell infiltration in the lamina propria (Plate 4 C) and severe depletion in the lymphoid follicles (Plate 4 D) were observed 15 days PI.

Liver

The hepatocytes showed mild degenerative changes associated with hyperemic central veins and sinusoids at 4 days PI. Diffuse proliferation of the kupffer cells with inflammatory cell infiltration in the portal area and dilatation in the central veins and sinusoids was seen by day 5 PI. Hyperemia in the central veins and sinusoids was also observed at 8, 10 and 13 days PI. At day 10 PI, the hepatic tissue showed focal necrosis associated with degeneration in the hepatocytes, and the central vein and sinusoids were hyperemic (Plate 5 A). Infiltration of inflammatory leucocytic cells in the necrosis area was seen at 15 days PI (Plate 5 B).

Kidney

Hyperemia of the blood vessels and capillaries of the stromal tissue and degenerative changes in the lining epithelial cells of the renal tubules were observed 4 days PI with focal hemorrhagic

areas at 8 days PI. Necrobiotic changes (coagulative necrosis) associated with severe hyperemia in the vascular blood vessels were seen in the renal tubules at 10 days PI (Plate 5 C). There was focal mononuclear leucocytic inflammatory cell infiltration in between the renal tubules at 15 days PI (Plate 5 D).

Serology

ELISA results indicated that SPF chicks inoculated with the proventricular homogenates had a mean titer of 6579 for IBDV when collected after 14 days PI. Testing of sera collected from inoculated SPF in the second and third passages revealed the presence of high titer of IBDV antibodies at 7 and 15 days PI (4677 and 6879, respectively). There were no detectable titers for any of the other tested agents in sera collected from inoculated chicks.

Isolation and characterization of the causative agent in SPF chicks

A transmissible infectious agent was isolated from the proventricular homogenates collected from field samples taken from 5 flocks in Fayoum governorate. The virus was successfully propagated in SPF chicks inducing proventriculitis. IBDV was detected in bursa of the inoculated chicks between 2 and 4 days PI, whereas testing the bursa or proventriculus after 6 till 8 days PI revealed negative results in the employed ELISA. The isolated virus react specifically with the utilized common Mab # 8 indicating that IBDV iso-

lated in the study is the possible principal cause of proventriculitis. After employing the ELISA on bursal tissue collected from inoculated SPF chicks in the first passage, the results indicated that the virus was present in tissues at 2 to 4 days PI. Therefore, in further passages in SPF chicks, the homogenates of proventriculus collected at 1, 2, 3 and 4 days PI were used for inoculation in the propagation of the isolated virus.

Antigenic typing of the isolated virus

The reactivity pattern of the isolated IBDV in the antigen capture ELISA employed in the study revealed that the isolated strain (designated as Fayoum/2003) belongs to the antigenic type related to Delaware variant strain (E/Del) of IBDV

Replication of the isolated IBDV in non-vaccinated commercial broiler chicks that have IBDV maternally derived antibodies

Inoculation of the isolated virus (pool of bursa and proventricular homogenates collected 1-4 days PI) in 6-8 days - old commercial broiler chicks that have high antibody titer to IBDV when measured by ELISA (Proflock plus IBD Ab test kit, Synbiotic, Europe, Lyon, France. The average mean titer of the inoculated chicks was 6578. This mean is considered a protective titer and corresponds to a virus neutralizing titer (VN) above 4 log₂ (the minimum protective titer for VN is 2 log₂ according to Synbiotics technical bulletin, October, 2001). Collection of the bursa from the inoculated chicks after 72 hours

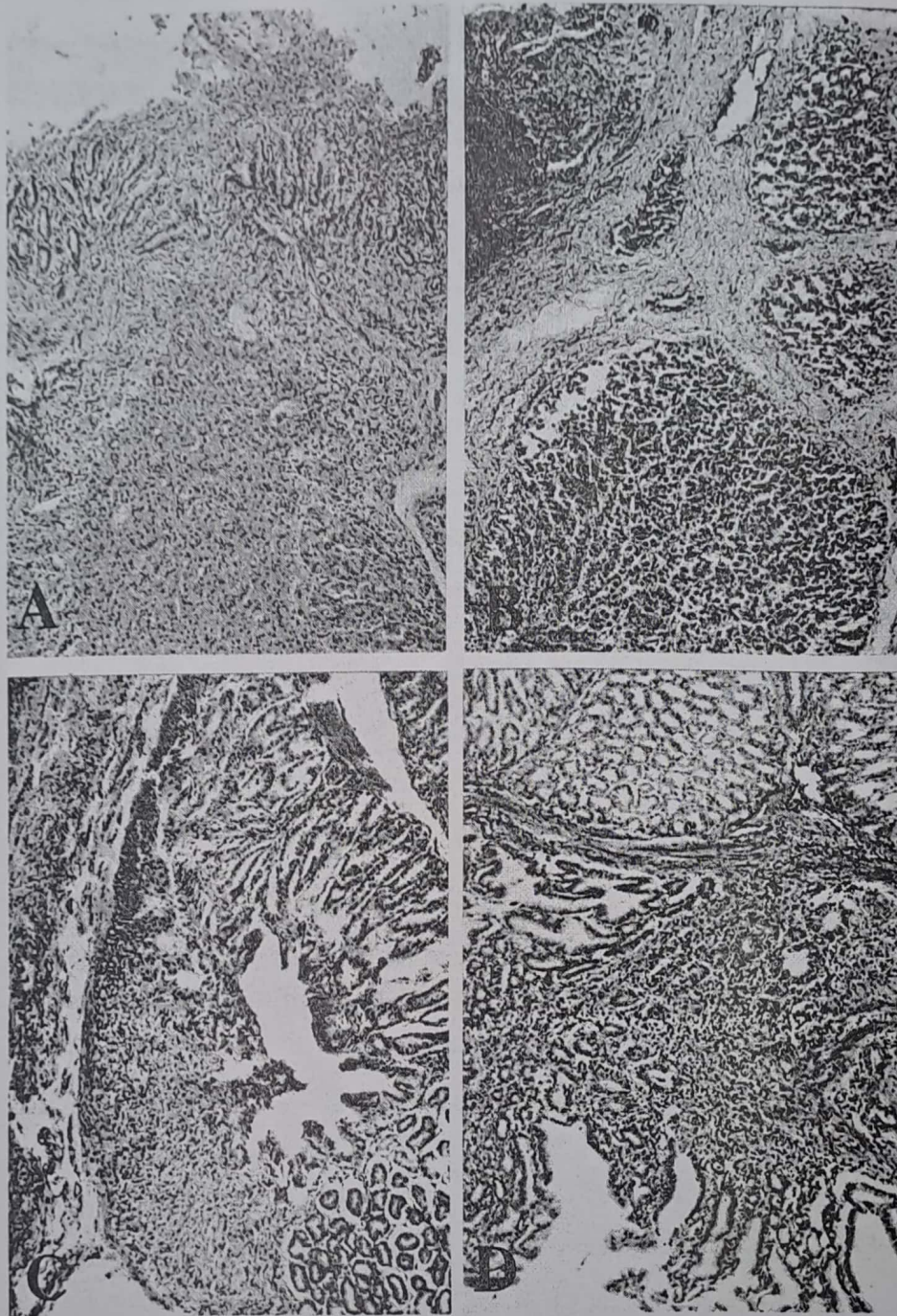


Plate (1): Histopathological changes observed in proventriculus after 2 (A), 4 (B), 5 (C) and 8 (D) days post inoculation in one-day-old SPF chicks. A and B on the top; C and D in the bottom.

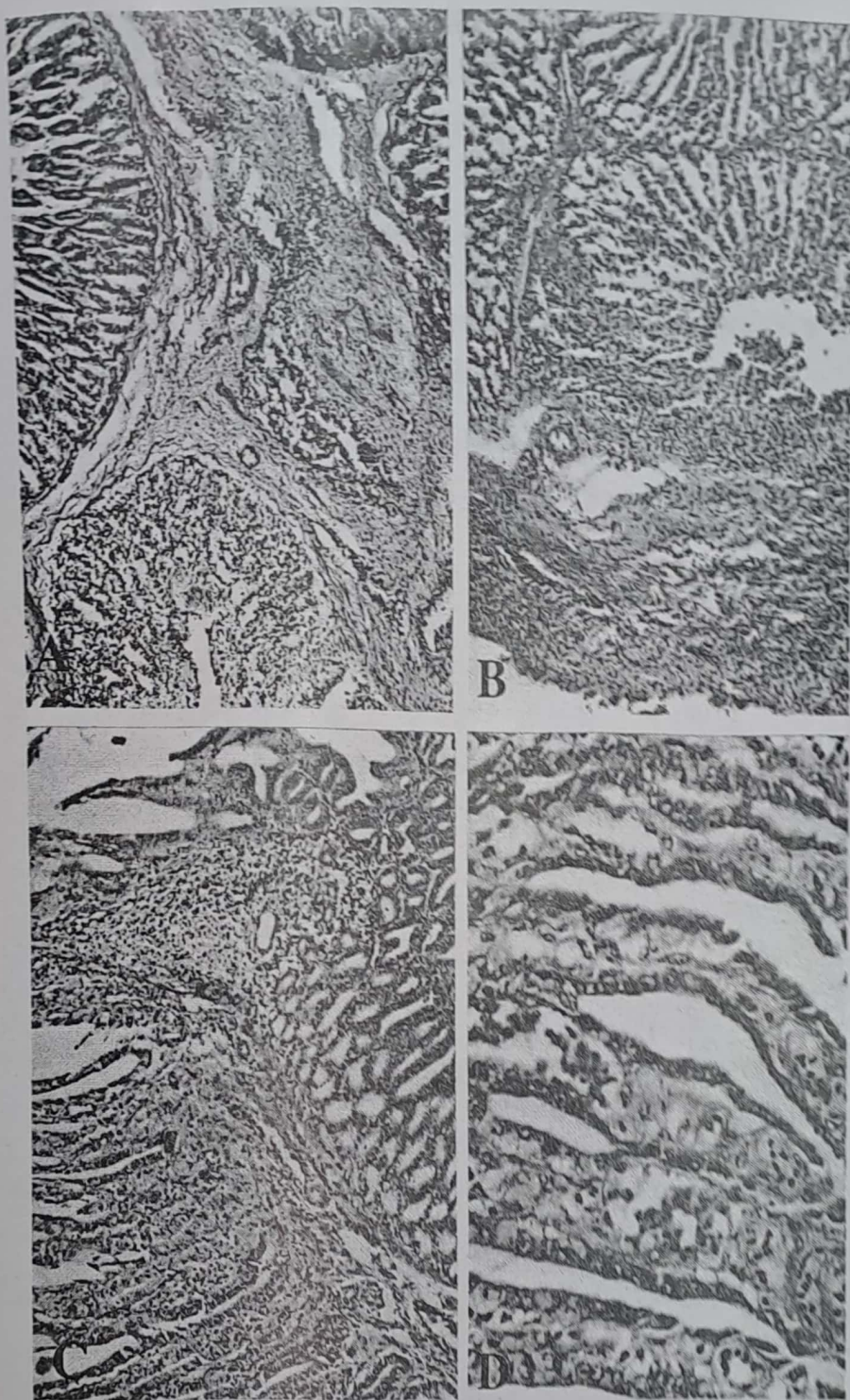


Plate (2): Histopathological changes observed in proventriculus after 8 (A), 13 (B), 15 (C and D) days post inoculation in one-day-old SPF chicks. A and B on the top; C and D in the bottom.

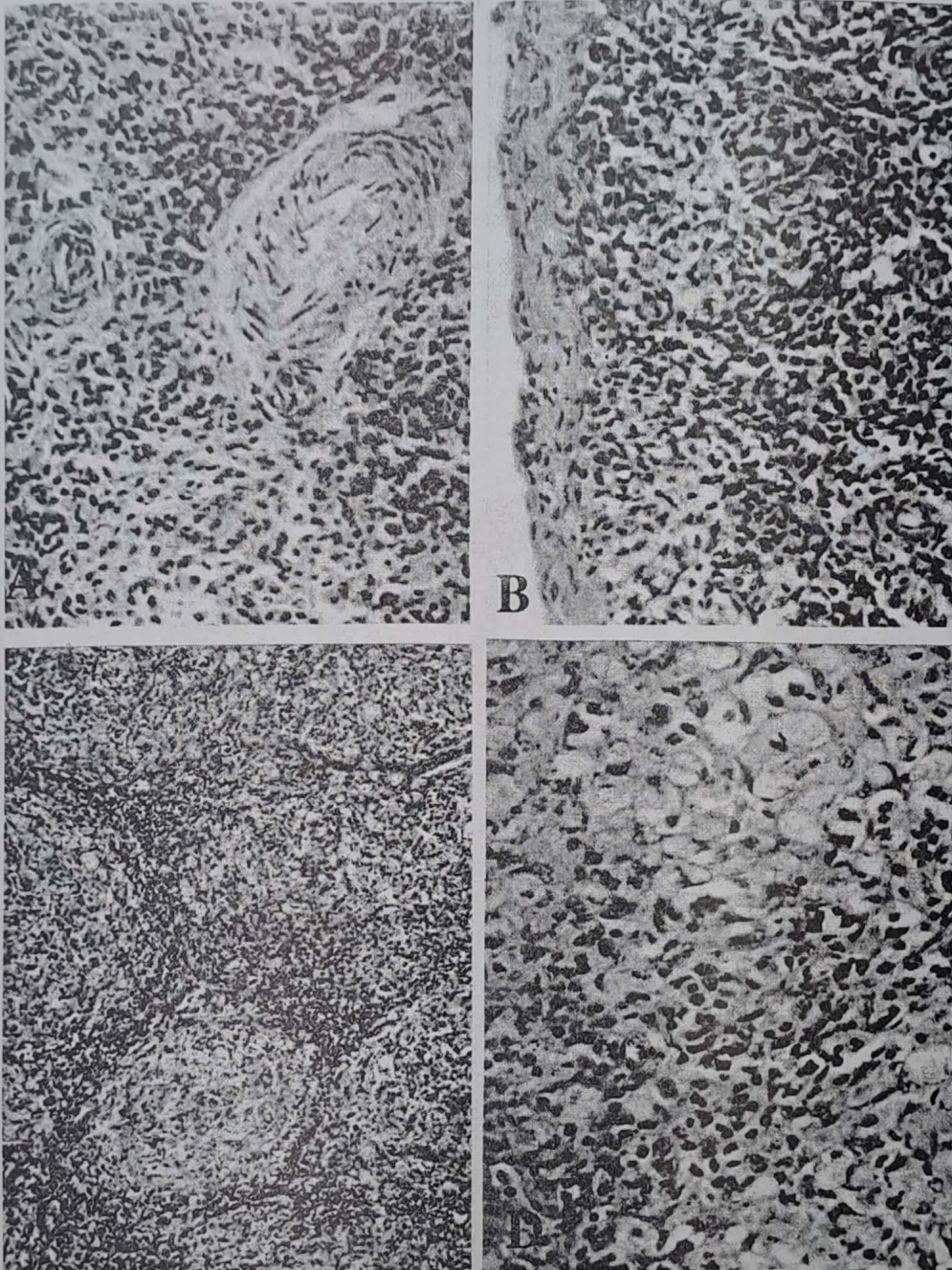


Plate (3) :Histopathological changes observed in spleen after 2 (A), 4 (B), 10 (C and D) days post inoculation in one-day-old SPF chicks. A and B on the top; C and D in the bottom.

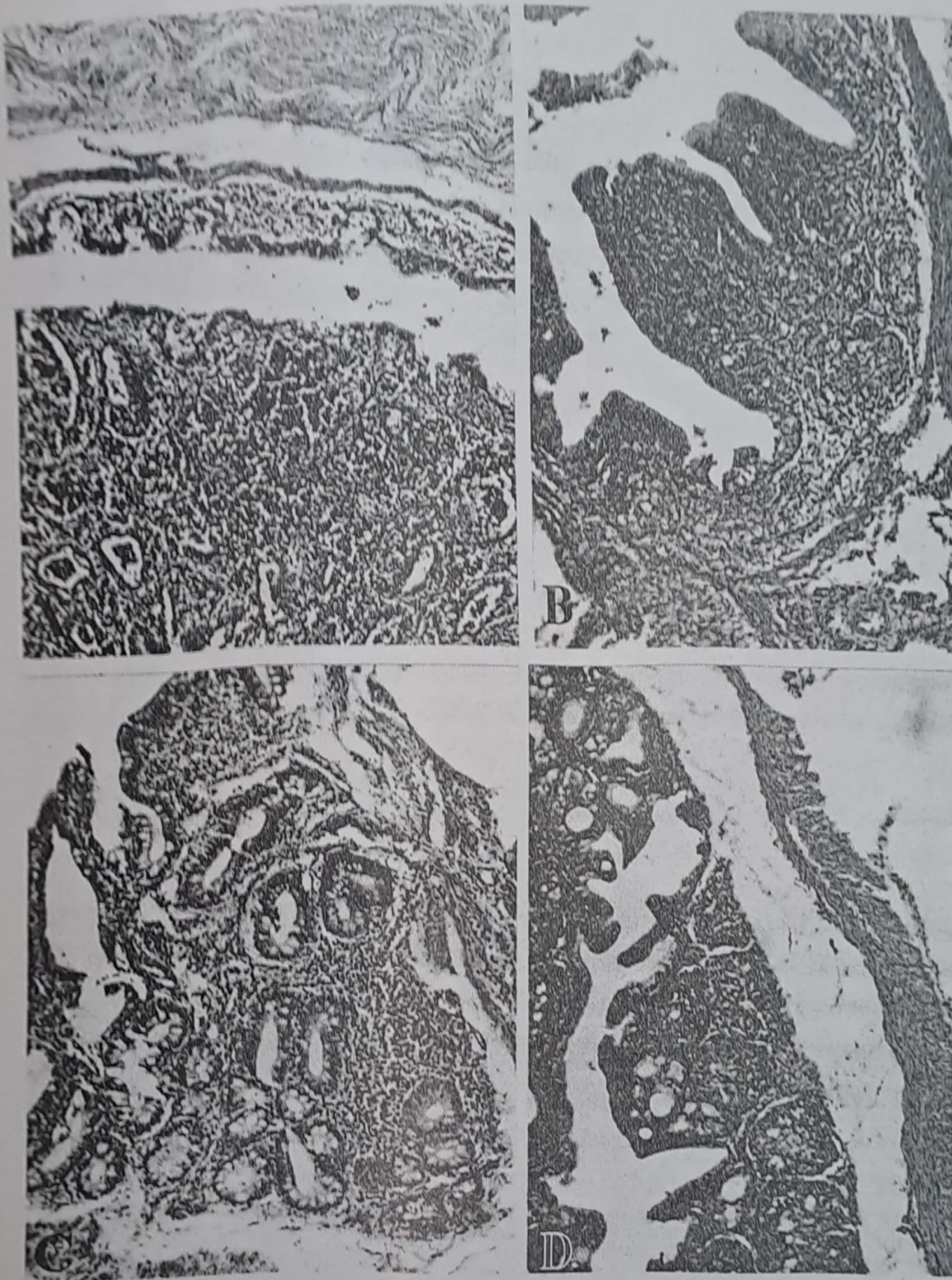


Plate (4): Histopathological changes observed in bursa of Fabricius after 2 - 4 (A), 10 (B), 15 (C and D) days post inoculation in one-day-old SPF chicks. A and B on the top; C and D in the bottom.

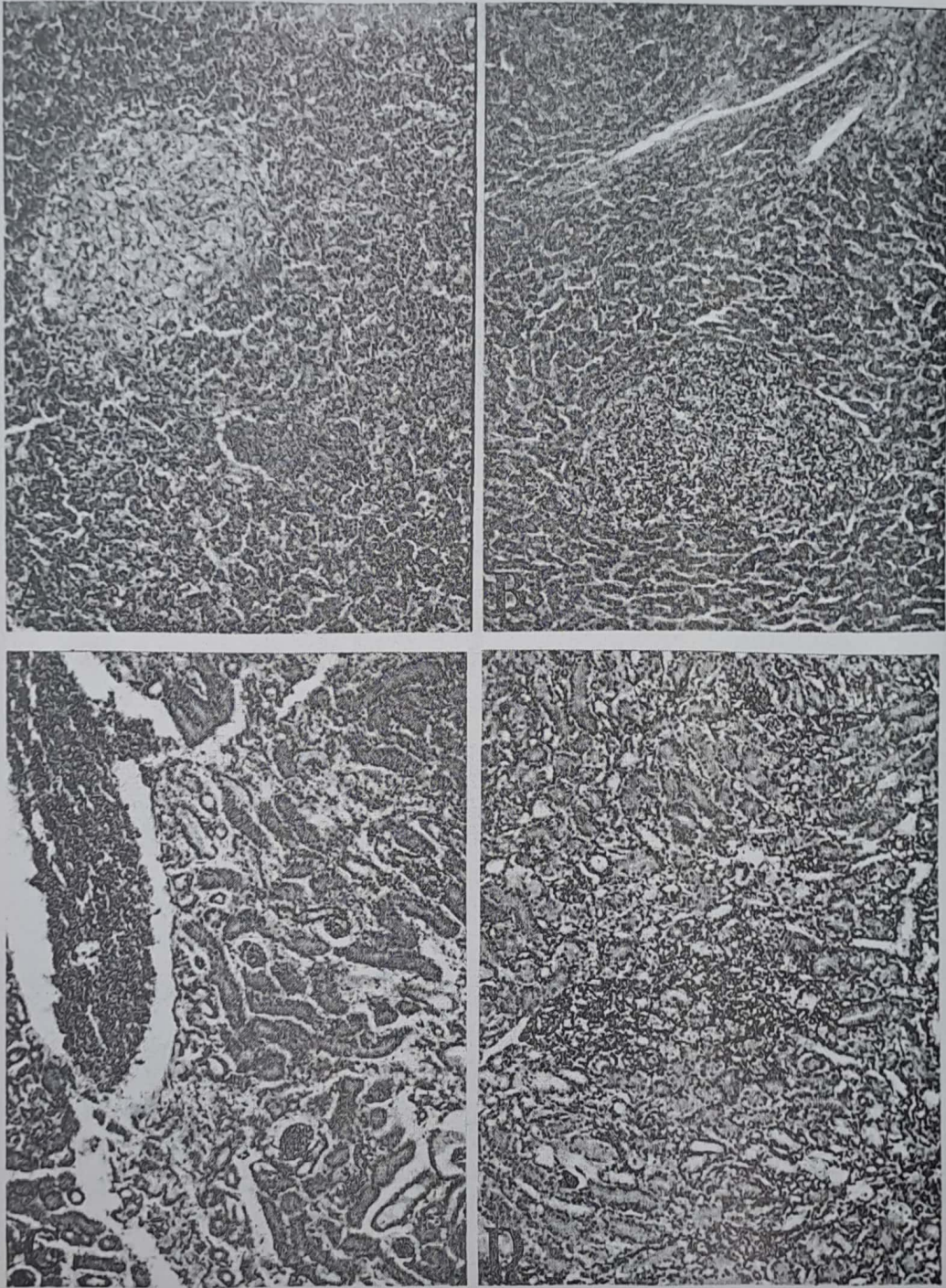


Plate (5): Histopathological changes observed after 10 and 15 days post inoculation in one-day-old SPF chicks in liver (A and B) and kidney (C and D). A and B on the top; C and D in the bottom.

PI and processing of its homogenate in the antigen capture ELISA, revealed the presence of IBDV, whereas the bursa collected from non-inoculated chicks were negative. Antigenic typing of the virus in the collected bursa by antigen capture ELISA using the above mentioned panel of Mabs revealed that the detected virus in the bursa was related to E/Del and confirmed the persistence of the virus in bursa for 3 days PI despite the presence of high mean titer of IBDV maternal antibodies at the time of inoculation. Therefore, the isolated IBDV variant strain (Fayoum/2003) breakthrough the maternal immunity even in the presence of high level of maternal antibodies (Those broiler came from breeders that have been vaccinated with classical strain vaccines).

Electron microscopy

Electron microscopic examination of grids containing samples collected from bursa of inoculated SPF or commercial non-vaccinated broiler chicks revealed the presence of virus particles in the cytoplasm of the cells. There was a population of particles, which were nearly similar. Photo 1 and 2 represent the detected virus particles in the cytoplasm and on the surface of cell membrane. The bursa samples examined were those collected after 72 hours PI in either SPF or commercial chicks. All of the samples were found to have similar virus particles confirming the success of isolation and propagation of the IBDV variant strain (proventricular IBDV).

Table (2): Antigen capture ELISA reactivity pattern of the isolated Fayoum/2003 proventricular IBDV strain

IBDV type	Mab # 8	Mab B 69	Mab R 63	Mab # 10
CLASSIC	+	+	+	+
CLS/ Y2K	+	-	-	+
E/Del	+	-	+	-
RS593/AL2	+	-	-	-
Fayoum/2003	+	-	+	-

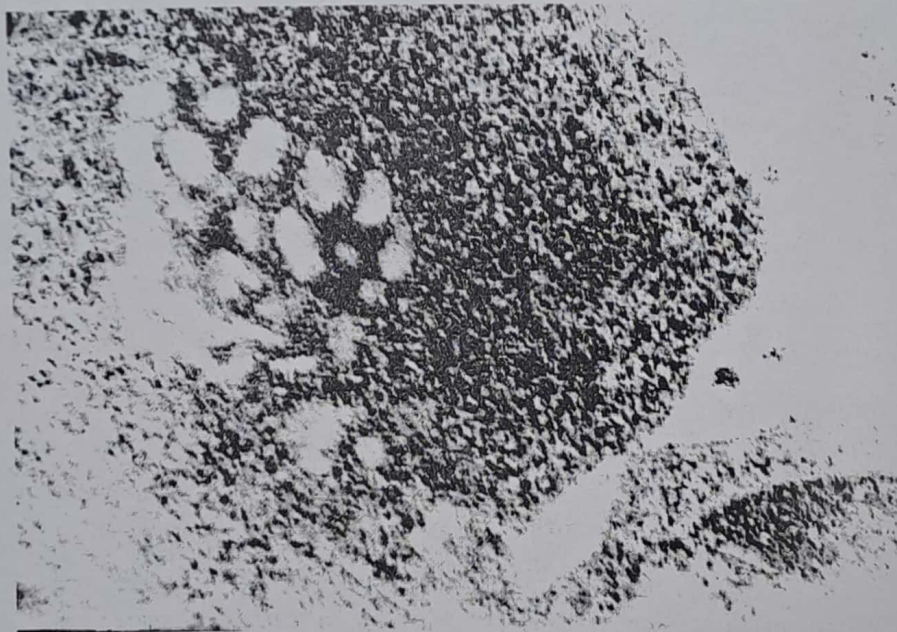
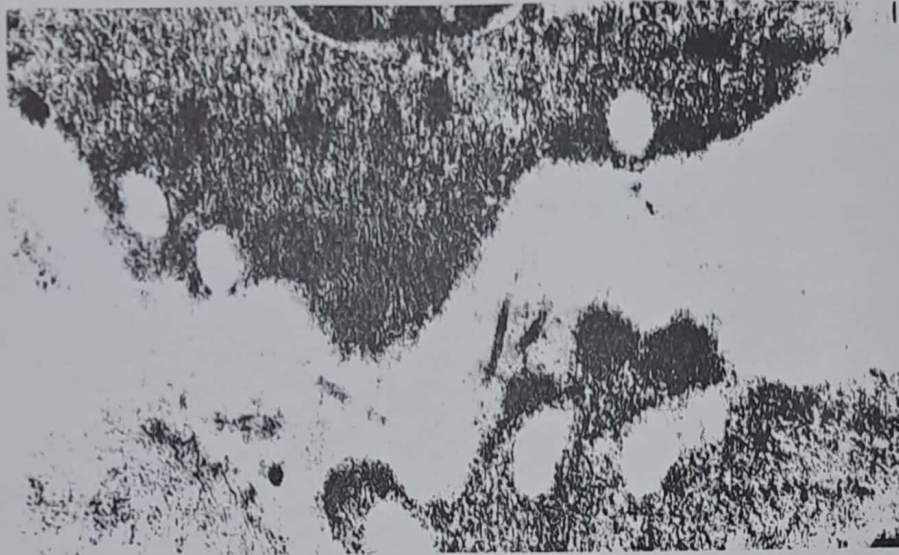

Photo 1 and 2: Transmission electron microscopic examination of bursa collected from inoculated SPF chicks after 72 hours PI. Virus particles were detected in the cytoplasm and cell membrane. (X 50,000).

DISCUSSION

The present study reports the isolation and characterization of IBDV associated with infectious proventriculitis and stunting syndrome in broilers in Egypt. Transmissible viral proventriculi-

tis has been previously described (Apple et al., 1991; Kouvenhoven et al., 1978; Bayyari et al., 1995; Goodwin et al., 1995 and 1996). The isolation of IBDV in the present study from the proventricular homogenates suggests that IBDV might be the cause of the transmissible viral

proventriculitis. This finding is consistent with the results of the recent work by Dormitorio et al. (2000). Also, other authors reported that IBDV may be a single possible etiology for proventriculitis, or play another perhaps more plausible role simply via its immune suppression effect (Cookson, 2001). On the contrary, some researchers reported the presence of adeno, reo or tumor inducing viruses associated with proventriculitis (Goodwin et al., 1996). Yet, IBDV was isolated and propagated with successful reproduction of the lesions in SPF chicks. Lesions produced in experimentally infected SPF chicks were identical to those reported for naturally infected chicks and coincided with other researchers (Cookson, 2001; Dormitorio et al. 2000). Transmission of infectious proventriculitis throughout the three conducted passages in day-old SPF chicks documents the potentiality of IBDV in changing its clinical face to survive and cause immunosuppression. Data presented in the current study strongly addresses the implication of variant strains of IBDV as the primary cause of the newly reported disease in broiler chicks in Egypt. Association of the disease with stunting syndrome confirms the effect of such IBD variants, and in general may reflect the effect of the antigenic variation on IBDV pathogenicity which might lead to an alteration in the clinical picture of the disease. In fact, the association of IBDV with infectious proventriculitis has been firstly reported in USA. Isolation of field variant strain of IBDV either from bursal or proventricular ho-

mogenates reported in the present study was similar to those reported in Alabama and Arkansas (Gaimbrone, 2001).

Histopathological changes observed in the proventriculus collected from the inoculated SPF chicks were similar to those reported by Goodwin et al., (1996). Necrosis in the glandular structure with inflammatory cell infiltration was characteristic (Reece, 2002). Although the pathogenesis of the transmissible viral proventriculitis is poorly understood, changes observed in the present study likely support the hypothesis of Goodwin et al. (1996) and the finding of Guy and Barnes (2003) that the clinical effects observed in the disease likely were due to the destruction of proventricular pepsinogen- and hydrochloric acid-secreting glandular epithelial cells (Goodwin and Hafner.,1997).

Atrophy and depletion in lymphoid cells seen in spleen and bursa observed in the present study after inoculation of the proventricular IBDV in SPF chicks were characteristic features to the variants IBDV (Dormitorio et al. 2000; Giambrone, 2001). The results confirm the earlier observation of Bayyari et al. (1995) however, we reported the thickening in the splenic capsule versus splenomegaly observed in their studies. The presence of IBDV maternal antibodies in commercial broiler chicks inoculated with the proventricular homogenate in the present study was similar to the previous studies of Bayyari et al. (1995) who

strongly incriminated IBDV in the proventriculitis. On the other hand, histopathological changes observed in the kidney were similar to those previously reported with IBDV (Henry et al. 1980; Okoye and Uzoukwu, 2001). Changes observed in liver resembled those observed with anemia and immunosuppression (Todd, 2000). Indeed, the sequential histopathology changes reported in the present study may increase our understanding of the pathogenesis of the proventricular IBDV.

This study indicates that the isolated proventricular IBDV is a variant strain and persists in the face of maternal immunity (derived from classic vaccines). This may be due to its antigenic variability. Escape of variant strain of IBDV in the presence of antibodies derived from classical vaccines has been previously reported (Snyder, 1990, Giambrone, 2001). Although other organs than the bursa may serve as non-bursal lymphoid tissues supporting the virus replication in case of persistence of such virus for long period, the study confirms the replication of the virus in the bursa. Differences in the immunopathogenesis of different IBDV strains have been recently studied (Silke et al., 2001). Nevertheless, the pathogenesis, immunogenicity and immunosuppression of the proventricular IBDV virus need to be addressed in further studies. Virus particles detected by electron microscopy (EM) in the present study support the finding of Guy and Barnes, (2003) who reported particles of 70 nm identified in thin sections which did not possess adeno-

viruses characters as previously reported by Goodwin et al. (1996). The EM examination employed in the study supports and confirms our isolation trails.

Not surprising is the isolation and identification of IBDV variant strains from Egyptian broiler flocks, specifically the E/Del strain. Previous reports in Egypt indicated the presence of IBDV variant strains (El-Sanousi et al., 1994; Sultan, 1995), and in very recent report by Metwally et al. (2003), who detected IBDV variant strains in broiler flocks in 58.3% of the tested bursae. The majority of the detected variants in such study were related to E/Del strain of IBDV. The extensive use of the live vaccines for several years to control the changed pathogenicity in IBDV strains may be the cause of continues evolution and mutation of IBDV or the immune selection under the extensive use of classical IBD vaccines. Researchers have shown that IBD field viruses continue to mutate and such antigenic variants are the cause of IBDV vaccination failure (Giambrone, 2001). The persistence of IBDV variants in vaccinated flocks for long time may be the source of the spread of these viruses as previously reported (Elankumaran et al. 2001). Therefore, it is important to re-evaluate the IBDV vaccination strategies in Egypt.

ACKNOWLEDGMENTS

We would like to thank Professor Dr. Ahmed. A. Samy for his critical reviewing of the manuscript

and suggestions; Professor Dr. Ismail M. Reda, Professor Dr. Mohamed S. Saber and professor Dr. Mohamed A. Shalaby for their helpful discussions and encouragements.

REFERENCES

- Apple, R. O., J. K. Skeeles, G. E. Houghten, J. N. Beasley, and K. S. Kim (1991). Investigation of a chronic feed-passage problem on a broiler farm in Northwest Arkansas. *Avian Dis.* 35: 422-425.
- Bancoft, J. D., A. Srevens, and D. R. Turner (1996). *Theory and practice of histological techniques*. 4th Ed. Churchill Livingstone, Eidenburgh, London, Melbourne, New York.
- Bayyari, G. R., W. E. Huff, J. M. Balog, N. C. Rath, and J. N. Beasley (1995). Experimental reproduction of proventriculitis using homogenates of proventricular tissue. *Poultry Science* 74†: 1799-1809.
- Cookson, k. C. (2001). Studies investigating the potential association between IBDV and infectious proventriculitis. *Partnerships in Poultry-Paris*, July 2001 30-33.
- Dormitori, T., J. Giambrone, F. Hoerr, T. Kelly, and S. Lockaby (2000) Is IBDV a cause of proventriculitis. *HighLights of Agricultural Research*, Winter,2000 Vol:47 Number 4.
- Elankumaran, S., heckert, R. A., and L. Moura, (2001). Persistence and distribution of a variant strain of infectious bursal disease virus in commercial broiler chickens. *International symposium on infectious bursal disease and chicken infectious anaemia*, Rauschholzhausen, Germany. Pp: 353-365.
- El-Sanousi, A. A., H. Madbouly, M. S. Saber, G. F. El-Bagouri, N. A. Abd- El-Bar, A. Batrawi and I. M. Reda (1994). Infectious bursal disease virus infection among Egyptian poultry flocks: III. Antigenic characterization of IBDV by the antigen capture ELISA (AC-ELISA) using monoclonal antibodies (Mabs). *Beni-Suef Vet. Med. Res.* 4: 300-307.
- Giambrone, J. (2001). IBD virus: an old foe changes its face again. *World Poultry- Elsevier special*01.
- Giambrone, J. (2002). Infectious Bursal Disease Virus: an old foe changes its face again. *Educational Development Magazine*, Feb pp: 10.
- Goodwin, M. A. and S. Hafner (1997). Transmissible viral proventriculitis. In†: *Diseases of Poultry*. 10th Ed. B. W. Calnek et al. (eds). Iowa State University Press, Ames, pp. 1034-1040.
- Goodwin, M. A., K. S. Latimar, E. Player, E. Niagro, and R. Campagnoli (1995). Viral proventriculitis in chickens, Program, 132nd Annual Meeting of the American Veterinary Medical Association. Pittsburgh, Pennsylvania, July 8-12, p 140.
- Goodwin, M. A., S. Hafner, D. Bounous, K. latimer, E. Player, E. Niagro, R. Campagnoli and J. Brown (1996). Viral proventriculitis in chickens. *Avian. Pathology*, 25, 369-379.
- Guy J. S. and H. J. Barnes, (2003). Experimental reproduction of transmissible viral proventriculitis; histopathological, immunohistochemical and ultrastructural findings. *Poultry health management*, College of Veterinary Medicine, North Carolina State University, Raleigh, NC, USA.
- Henry, C. W., r. N. Brewer, S. A. Edgar, and B. W. Gray (1980). Studies on infectious bursal disease in chickens. 2. Scoring microscopic lesions in the bursa of Fabricius.

- thymus, spleen and kidney in gnotobiotic and battery reared White Leghorns experimentally infected with infectious bursal disease virus. *Poultry Science* 59: 1006-1017.
- Huff, G. R., Q. Zheng, L. A. Newberry, W. E. Huff, J. M. Balog, N. C. Rath, K. S. Kim, E. M. Martin, S. C. Goeke, and J. K. Skeeles (2001). Viral and bacterial agents associated with experimental transmission of infectious proventriculitis of broiler chickens. *Avian Dis.* Oct-Dec 45: 828-43.
- Kouwenhoven, B., F. G. Davelaar, and J. Van Walsum (1978). Infectious proventriculitis causing runting syndrome in broilers. *Avian Pathology*, 7, 183-187.
- Kouwenhoven, B., Vertommen, M. H. and E. Goren (1986). Runting in broilers, in: J. B. McFerran and M. S. McNulty (Eds) *Acute virus infections of poultry*, pp. 165-178 (Dordrecht, The Netherlands, Martinus Nijhoff).
- MartLand, M. F. (1989). Advances in runting stunting syndrome research, in R. Pandy (ED.) *Progress in Veterinary Microbiology and Immunology*, Vol. 5. *Non-oncogenic Avian Viruses*, pp. 109-133 (Basel, Karger).
- Metwally, A. M., M. Z. Sabry, M. M. Omer, A.A. Yousif and I. M. Reda Direct detection of variant infectious bursal disease virus in vaccinated Egyptian broiler flocks using antigen-capture ELISA. *Vet. Med. J., Giza*. Vol. 51, No 1: 105-119.
- Okoye, J.O.A. and M. Uzoukwu, (2001): Histopathogenesis of a local isolate of infectious bursal disease virus in broilers. *International symposium of infectious bursal disease virus in broilers. International symposium on infectious bursal disease and chicken infectious anaemia, Rauschholzhausen, Germany*. Pp: 366-383.
- Reece, R. L. (2001). Infectious stunting syndrome and related diseases. In *Poultry Diseases*, 5th ed. Eds: Jordan, F, Pattison, M, Alexander, D, and Faragher, T: Saanunders, London: pp374-383.
- Reece, R. L. (2002). Infectious proventriculitis and stunting syndrome of broiler chickens. A report to RIRDC, Canberra, March: 66pp, 1 table, 31 Figures.
- Silke, R., H. Yeh, and J. M. Sharma (2001). A comparison of the immunopathogenesis of different IBDV strains. *International symposium on infectious bursal disease and chicken infectious anaemia, Rauschholzhausen, Germany*. pp: 311-323.
- Snyder, D. B. (1990). Changes in the field status of infectious bursal disease virus. *Avian Pathology* 19: 419-423.
- Snyder, D. B., P. K. Savage, S. A. Megel, V. N. Vakharia, and D. Luticken (1994). Molecular epidemiology of infectious bursal disease virus in the United States. *International symposium on infectious bursal disease and chicken infectious anaemia, Rauschholzhausen, Germany*. Pp: 65-70.
- Sultan, H. A. (1995). Studies on infectious bursal disease in chickens. PhD Thesis, Fac. Vet. Med., Alexandria Uni.
- Todd, D. (2000). Circoviruses: immunosuppressive threats to avian species: a review. *Avian Pathology* 29: 373-394.