

IMMUNOPOTENTIATION PROPERTIES OF PROPIOBACTERIUM GRANULOSUM VERSUS VITAMIN E IN CYLOPHOSHAMIDE IMMUNOSUPPRESSED CHICKENS.

MANAL A. AFIFY, O. A. ELSHAZLY, SAHAR A. ZOUELFAKAR, IMAN B. SHAHEED
and M. H. H. AWAAD

Faculty of Veterinary Medicine, Cairo University.

Received: 1. 3. 2003

Accepted: 30. 3. 2003

SUMMARY

The immunosuppressing effect of cyclophosphamide (CP) on cell mediated and humoral immunity has been proven with severe dramatic effect on serum transferrin (Tf) and immunoglobulins (IgG and IgM). Marked alterations in the morphologic features of major lymphoid organs and their weight / body weight indices were evident.

The immunoassay revealed that Propiobacterium granulosum immunopotentiated the production of anti-sheep red blood cells (SRBCs) haemagglutinating (HA) antibodies 7 days post immunization till the end of the experiment (42 days) with a geometric mean ranging between 1.8-5.1. While vitamin E humbly sustained the HA titer at 14 and 21 days post immunization with a geometric mean of only 0.5 for each. Administration of Propiobacterium granulosum and vitamin E highly improved the level of serum Tf, IgG and IgM dur-

ing the entire period of the experiment. They also significantly increased stimulation indices of lymphocyte transformation 7-14 days post immunization with SRBCs. Bursal / body weight index was significantly increased at 14 and 21 days post treatment with Propiobacterium granulosum and at 21 days post treatment with vitamin E over CP immunosuppressed non-treated control chickens. Histomorphologic features of bursa of Fabricus, thymus gland and spleen were markedly improved with Propiobacterium granulosum and vitamin E by post treatment day 7 and onwards.

Protection percentage against E.coli challenge in the bioassay study reached 84.4 % or 68.9 % in CP immunosuppressed chicken groups immunopotentiated with Propiobacterium granulosum or vitamin E respectively as compared with 48.9 % in immunosuppressed non-immunopotentiated group.

INTRODUCTION

Alteration in any step involved in the host's immunologic reaction potentiates normal immune response in poultry. Undoubtedly; immunosuppression would lead to immunodeficiency. The latter has a dramatic effect on the host health, which subsequently leads to urgent need for immunopotentiators as a matter of compensation.

Awaad et al. (2000, b) investigated the immunomodulating effect of inactivated propiobacterium granulosum preparation versus vitamin E. The aim of this study is to challenge their immunomodulating effect in cyclophosphamide immunosuppressed chickens.

MATERIAL AND METHODS

Inactivated Propiobacterium granulosum with L.P.S. of bacteria cells produced by Calier laboratories les Franqueses del valles (Barcelona) Espana under the trade name "IM-104" was used.

Vitamin E. 10% vitamin E selenium was used.

Experimental chickens. A total of 327, day-old meat type chickens were divided into 8 groups (1-8). The first 7 groups were consisting of 45 each. While the last 8th. group was consisting of 12 birds. All birds were housed in separate, wire-floored pens and fed on a commercial balanced ration ad libitum. The chickens were vaccinated against Newcastle disease using Hitchner and La

Sota vaccines at 5 and 18 days of age respectively.

Haemagglutination test. This was carried out after Anon (1971).

Lymphocytic transformation test. This was applied after Charles et al. (1978) and Lucy (1984). Separation of lymphocytes was adopted after Boyum (1968). Determination of viable cell number was carried out according to Hanks and Wallace (1958). Culturing of lymphocytes was performed as described by Confer et al (1981 using phytohaemagglutinin-P at a concentration of 10 µg/well. Evaluation of lymphocyte blastogenesis response using modified MTT dye uptake assay was adopted after Garn et al. (1994). The response of lymphocyte was given in terms of stimulation index according to Carpenter et al (1978).

Polyacrylamide gel electrophoresis (PAGE). PAGE was carried out as described by Maurer (1971) using the alternative method with gel system No.1 a (pH 8.9, 7%).

Statistical analysis. This was adopted after Snedecor (1956) and Cochran and Cox (1960).

Experimental design. Chickens of groups 1-6 were immunosuppressed after Al-Afaleq and Jones (1991). by subcutaneous inoculation of 4 mg / bird with cyclophosphamide (CP) (Endoxan.

ASTA Medica AG, Germany) in sterile distilled water at one, two and three days of age. Birds of groups 1-2 and 3-4 received Propiobacterium granulosum and vitamin E in a dose of one ml/l drinking water at 1-5 days of age respectively.

For immunoassay: chickens of groups 1, 3, 5 and 7 were immunized intramuscularly at 2 day-old with sheep red blood cells (SRBCs) suspension in a dose of 10 mg / bird. Individual blood samples were taken from the immunized groups by heart puncture at 3, 7, 10, 14 and 21 days post inoculation. Blood samples were subjected to lymphocyte transformation test. Serum samples were also separated for HA test and equal samples from each group were pooled for PAGE analysis. Feed consumption and final body weight of birds of groups 1, 3, 5 and 7 were carried out at the end of the crop (42 days) for feed conversion ratio (FCR) determination. Three chickens out of each group were sacrificed at 3 days post CP treatment as well as 3, 7, 14 and 21 days post SRBCs immunization (PSRBCsI). Bursa of Fabricus, spleen and thymus gland were weighted for determination of the relative bursal, spleen and thymus weight indices after Sharma et al. (1989) by the following equation: organ weight in grams X 1000 / total body weight in grams.

For histomorphological examination; specimens including bursa of Fabricius, thymus and spleen

were collected from chickens of the immunized chicken groups as well as from the blank control, kept in 10 % formal saline, routinely processed and stained with H and E.

For bioassay; chickens of groups 2,4 and 6 were subcutaneously challenged with 10^8 CFU of E.coli serogroup O78 at 12 day-old and were kept under observation for clinical signs and mortality for 3 weeks. Specimens from heart, liver, lungs and kidneys were collected from groups 2,4,6 and 7 and were similarly treated.

RESULTS

Obtained results are shown in tables 1-4 and Figs 1-4.

Histomorphological changes of immunoassay observed at 3 days PSRBCsI were similar in CP treated non-immunomodulated birds as well as in CP treated immunomodulated ones either with Propiobacterium granulosum or vitamin E. Mild to moderate depletion of lymphocytes in the spleen and the medulla of the thymic lobules and an almost complete depletion of lymphocytes in the cortex and medulla of the bursal follicles associated with reticular cell hyperplasia were commonly observed in all birds (Fig. 1A). By the 7th day, the CP treated birds showed progressive atrophy of the bursal follicles, fibrous thickening of

the interfollicular stroma and complete depletion of lymphocytes both in the medulla and cortex together with reticular cell hyperplasia (Fig. 1B). The spleen and thymus of such birds showed lesions similar to those observed 3 days post CP treatment. In birds immunomodulated either with vitamin E or *Propiobacterium granulosum*, the bursal follicles were less severely atrophied though, thickening of interfollicular stroma was still evident. Few activated lymphoblasts began to appear in the medulla of some bursal follicles and thymic lobules (Fig. 1C). The bursal follicles 14 days post CP treatment appeared markedly atrophied, centrally vacuolated and widely separated by edematous fibrous stroma (Fig. 1D), whereas in immunomodulated birds the number of activated lymphoblasts and lymphocytes significantly increased particularly in *Propiobacterium granulosum* treated birds (Fig. 1E). Depletion of lymphocytes in the medulla of thymic lobules, atrophy and depletion of splenic lymphoid follicles associated with heterophile cell infiltration were obvious in CP treated bird (Fig. 1F). In contrast, those of immunomodulated birds were mildly affected. By the day 21, lesions in the bursal follicles of CP treated birds were more progressive, they were markedly atrophied, fewer in number and were widely separated by edematous interfollicular stroma (Fig. 2A). Thymic lobules of such birds showed moderate to marked depletion of lymphocytes in the medulla (Fig. 2B). The

bursae of immunomodulated birds revealed numerous lymphoid follicles containing variable numbers of lymphocytes and activated lymphoblasts. Some follicles were obviously regenerated particularly in *Propiobacterium granulosum* immunomodulated birds (Fig. 2C). While the thymus almost appeared normal (Fig. 2D). Thymus, bursa and spleen of non-treated non-modulated birds appeared normal throughout the period of the experiment (Fig. 2E & F).

Histopathological changes of the bioassay observed in birds immunosuppressed by CP and infected with *E. Coli* were much more severe and widespread as compared with those found in birds treated with CP and immunomodulated either with vitamin E or *Propiobacterium granulosum* post infection with *E. coli*.

Liver: Immunosuppressed, *E. coli* infected birds revealed marked vacuolar degeneration of hepatocytes, multifocal areas of hepatic necrosis, hyalinization and mononuclear cell infiltration (Fig. 3A) and multiple area of hemorrhage and hepatic cell dissociation (Fig. 3B). Birds immunomodulated with vitamin E or *Propiobacterium granulosum* showed mild vacuolar degeneration of hepatocytes, sporadic aggregates of mixture of hepatocytes, macrophages and heterophiles associated with hepatic cell necrosis and in some cases periportal heterophile cell infiltration. (Fig.

3C&D).

Kidneys: Immunosuppressed non-modulated birds showed acute diffuse non-suppurative interstitial nephritis. The renal tubules were replaced and widely separated by lymphocytes and macrophages (Fig.3E), whereas in immunomodulated birds sporadic focal lymphoid aggregates were observed in some cases (Fig.3F). Areas of hemorrhages and dissociated renal parenchyma were observed (Fig. 4A) in immunosuppressed, non-modulated birds.

Heart: CP treated birds showed acute severe pericarditis and myocarditis. The pericardium was markedly thickened by edema, congestion and

cell infiltration mostly heterophiles (Fig.4B). The myocardium was moderately infiltrated with mononuclear cells and heterophiles (Fig. 4C). Immunomodulated birds revealed mild pericarditis and limited subepicardial myocarditis (Fig.4D).

Lung: The lungs of CP treated birds showed severe bronchitis, manifested by desquamation of bronchial epithelium, peribronchial edema and cell infiltration (mostly heterophiles), cell debris and desquamated cells in the bronchial lumen (Fig.4E&F). Whereas no such lesions were recorded in immunomodulated birds. In addition to bursal and thymic changes no significant lesions were observed in other organs.

Table 1: Immunomodulatory effect of *Prpriebacterium granulorum* and vitamin E on lymphocyte transformation, haemagglutinin antibody response and feed conversion ratio (FCR) of cyclophosphamide (CP) treated chickens immunized with sheep red blood cells.

Gr No.	Treatment			Stimulation index of lymphocyte transformation measured by MTT (Days post immunization)					Haemagglutinin antibody titer (Days post immunization)					Final Body Wt.	Feed Consumption	FCR		
	Imm. Stim.	Sheep RBCs	CP	0	3	7	10	14	21	0	3	7	10				14	21
1	Vit. E.	+	+	1.31 ± 0.1	0.79 ± 1.2	1.00* ± 0.6	1.09* ± 0.76	1.26* ± 0.09	1.19 ± 0.73	0	0	0	0	0.5	0.5	1479.3 ± 24.1	3670.40	2.48
2	IM-104	+	+	1.31 ± 0.1	0.81 ± 0.9	1.12 ± 0.8	1.28* ± 0.2	1.90* ± 0.72	1.5 ± 2.3	0	0	1.8	4.8	5.0	5.1	1548.5 ± 15.7	3720.40	2.4
3	Positive control	+	+	1.31 ± 0.1	0.70 ± 0.7	0.80 ± 0.9	0.86 ± 0.65	0.99 ± 1.2	1.03 ± 0.92	0	0	0	0	0	0.5	1332.1 ± 9.90	3153.99	2.36
4	Negative control	+	-	1.31 ± 0.1	1.2 ± 0.04	1.19 ± 0.32	1.3 ± 0.014	1.2 ± 0.247	1.08 ± 0.024	0	3	5.1	5.6	5.5	4.5	1393 ± 30.1	2950.9	2.11

* Significant increase at P<0.05.

Table 2: Effect of *Propriobacterium granulosum* and vitamin E on weight indices of lymphoid organs of experimented chickens.

Gr No.	Treatment			Time of testing														
	Imm. Stim.	Sheep RBCs	CP	Days post sheep RBCs immunization														
				3 days post CP treatment			3			7			14			21		
				B/ BWt	Sp/ BVt	T/ BWt	B/ BWt	Sp/ BVt	T/ BWt	B/ BWt	Sp/ BVt	T/ BWt	B/ BWt	Sp/ BVt	T/ BWt	B/ BWt	Sp/ BVt	T/ BWt
1	Vit. E.	+	+	1.8	3.4	7.8	2.1	3.1	9.2	3.9	6.1	10.7	3.6	3.4	11.7	6.3*	5.1	18.9
2	IM-104	+	+	1.8	3.4	7.8	1.9	3.0	9.2	3.8	6.1	9.9	4.1*	5.1	14.4	6.1*	7.4*	15.7
3	control +ve.	+	+	1.8	3.4	7.8	2.2	3.2	9.3	3.1	6.3	10.6	3.1	3.6	12.3	5.5	5.1	17.3
4	control -ve	+	-	9.57	3.05	13.03	12.77	14.7	12.24	17.67	10.41	34.57	19.84	7.48	32.61	25.07	10.02	29.01

* Significant increase at $P < 0.05$.
CP = Cyclophosphamide index.

B/B. Wt. = Bursa/body weight index
Imm. Stim. = Immune stimulant.

Sp/ B. Wt. = Spleen / Body weight index.
T/B. Wt. = Thymus/Body weight.

Table 3: Results of *E. coli* serogroup O78 infection to *Propriobacterium granulosum* and vitamin E immunopotiated chickens previously immunosuppressed by cyclophosphamide (CP).

Gr. No.	Treatment	CP Treatment.	Mortality %	Protection %
2	Vit. E	+	31.1%	69.9%
4	IM-104	+	15.6%	84.4%
6	Control	+	51.1%	48.9%

Table 4: The immunomodulatory effect of Vitamin E. and *Prriobacterium granulosum* on IgM, IgG and serum transferrin of immunosuppressed chickens with cyclophosphamide.

Group No.	Treatment	Effect on IgM					Effect on IgG					Effect on Tf				
		7	10	14	21	7	10	14	21	7	10	14	21			
1	Vit. E.	11.83	6.24	8.22	8.52	9.05	17.48	11.41	9.81	6.24	6.99	8.83	8.01			
2	IM-104	6.71	11.05	10.54	11.62	7.52	18.48	13.26	14.88	10.12	10.04	9.55	5.44			
3	Positive control	0.82	1.86	1.92	6.16	0.07	3.51	1.72	3.56	0.00	1.05	1.95	1.52			
4	Negative control	8.50	5.43	9.98	9.53	7.27	5.87	11.92	17.99	7.14	15.84	8.66	4.27			

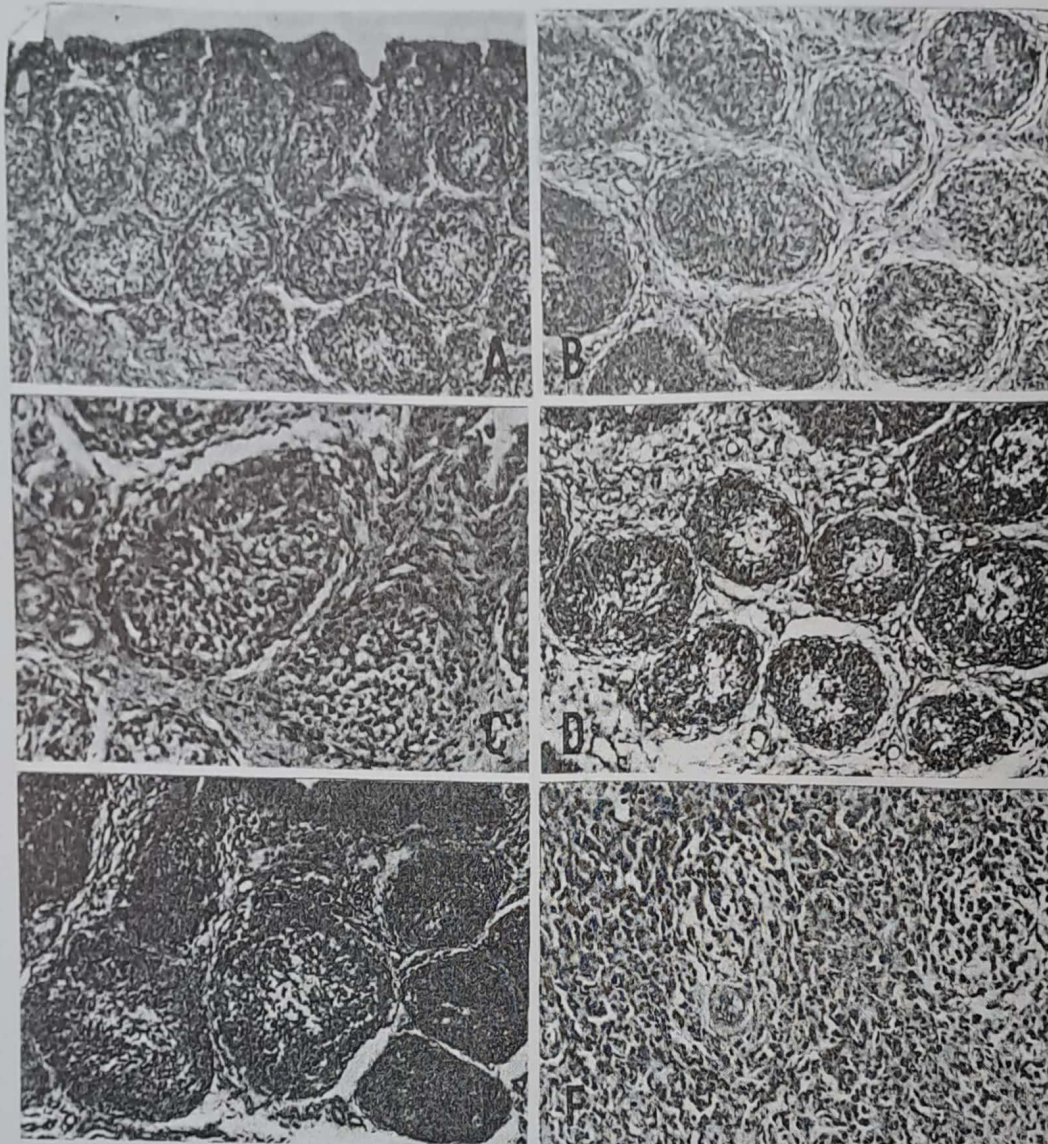


Fig. 1: A, Bursa of Fabricius (BF) of CP treated birds 3 days post treatment showing an almost complete depletion of lymphocytes in the bursal follicles (H&E X33). B, BF 7 days post immunosuppression with CP, showing progressive atrophy of bursal follicles reticular cell hyperplasia and fibrous thickening of interfollicular stroma (H&E X66). C, BF of IM 104 treated birds showing activated lymphoblasts and lymphocytes in the medulla (H&E X 132). D, BF of immunosuppressed birds 14 days PCPT showing marked atrophy of bursal follicles which are centrally vacuolated and widely separated by edematous fibrous stroma (H&E X66). E, Bursa of Fabricius of birds treated with vitamin E 14 days post treatment, showing increased number of activated lymphoblasts and lymphocytes in the bursal follicles (H&E X66). F, Spleen of immunosuppressed birds 14 days PCPT showing marked depletion of lymphocytes and heterophile cells infiltration (H&E X66).

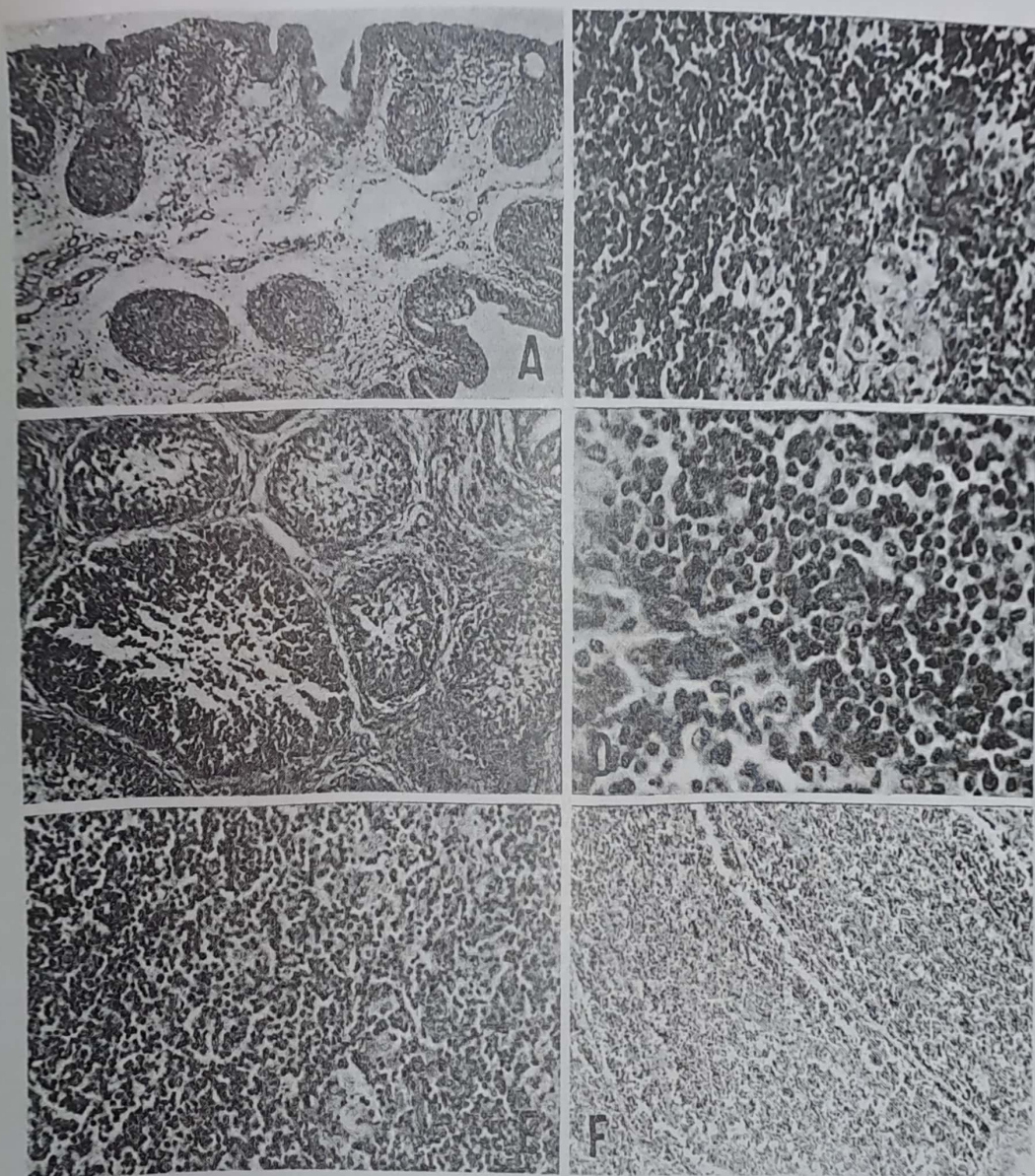


Fig. 2: A, BF of birds immunosuppressed with CP 21 days showing severely atrophied bursal follicles which are separated by edematous stroma (H&E X 33). B, Thymus of immunosuppressed birds 21 days PCPT showing depletion of lymphocytes in the medulla of thymic lobules (H&E X66). C, BF of Propiobacterium granulosum treated birds showing regenerating bursal follicles filled with lymphocytes (H&E X 33). : D, Thymus of Vitamin E treated birds 21 days showing nearly normal thymic medulla (H&E X 132). E, Thymus of control non-immunosuppressed, non-treated birds showing normal structures (H&E X33). E, Thymus of control non-immunosuppressed, non-treated birds showing normal structures (H&E X33). F, Bursa of control non-immunosuppressed, non-treated birds showing normal bursal follicles filled with lymphocytes (H&E X 33).




Fig. 3: A, Liver of immunosuppressed E coli infected birds showing marked vacuolar degeneration of hepatocytes, areas of hepatic necrosis and mononuclear cell infiltration (H&E X 132). B, Liver of the same birds showing hemorrhage and hepatic cell dissociation (H&E X33). C, Liver of immunosuppressed immunomodulated birds challenged with E coli showing focal areas of hepatic cell necrosis and infiltrated with mixture of lymphocytes, macrophages and heterophiles (H&E X 132). D, Liver of the same birds showing periportal heterophile cell infiltration (H&E X 66). E, Kidney of immunosuppressed - E coli infected birds showing acute diffuse lymphocytic interstitial nephritis (H&E X 33). F, Kidney of immunosuppressed, immunomodulated birds showing sporadic focal lymphoid nodules (H&E X 33).

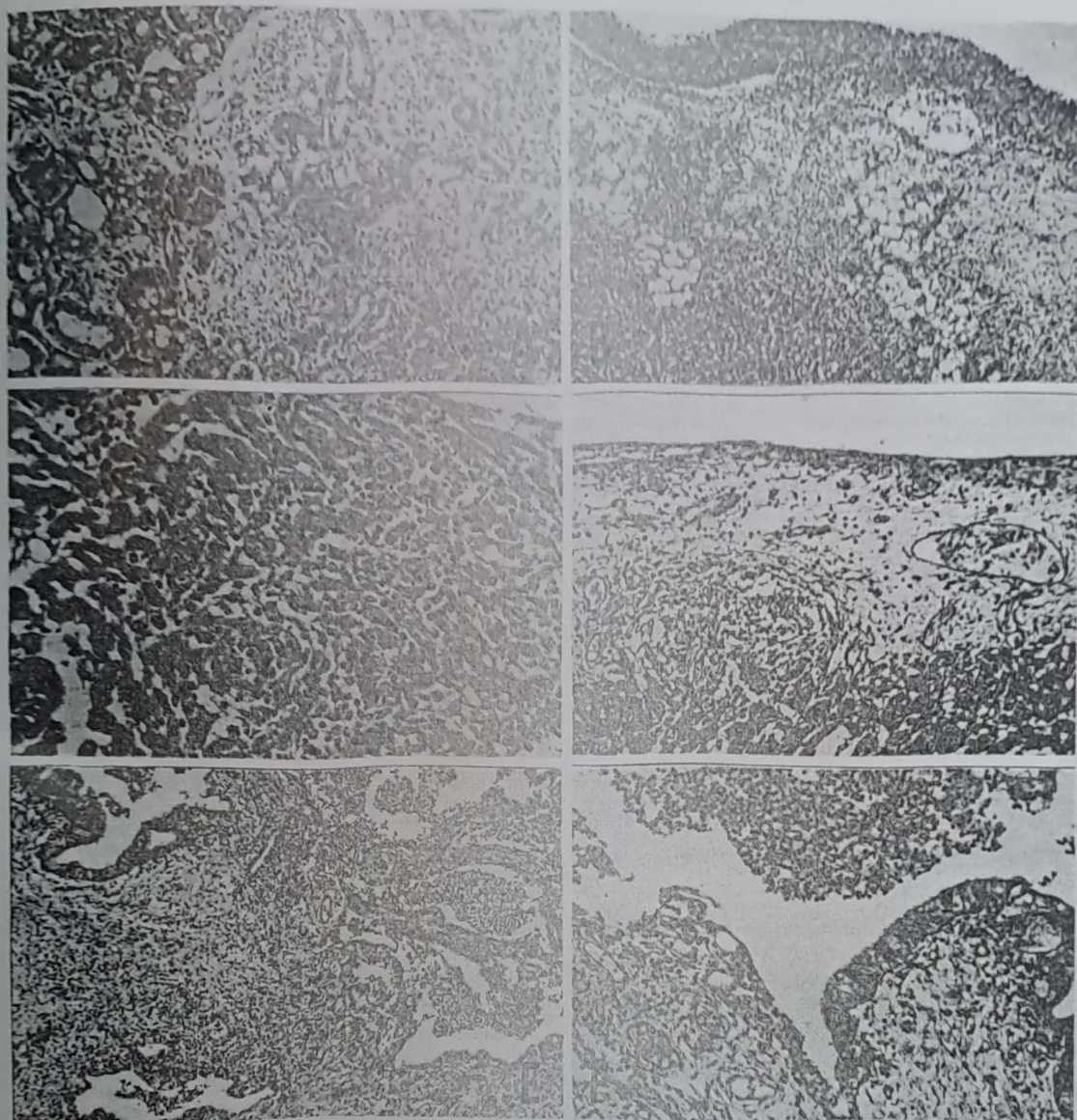


Fig. 4: A, Kidneys of immunosuppressed -E coli infected birds showing renal hemorrhage and dissociation of renal tubules (H&E X 33). B, Heart of same birds showing acute pericarditis, the pericardium appeared thickened with edema, congestion and inflammatory cells infiltration mostly heterophiles (H&E X 33). C, Heart of the same birds showing infiltration of the myocardium with lymphocytes, macrophages and heterophiles (H&E X 66). D, Heart of immunosuppressed immunomodulated birds showing moderate pericarditis. The pericardium appeared thickened with edema and cellular infiltrates. (H&E X 66). E, Lung of immunosuppressed birds showing severe bronchitis and peribronchial heterophile cell infiltration (H&E X 33). F, Higher magnification of Fig. 2E showing desquamation of bronchial epithelium (arrow) peribronchial heterophile cell infiltration and intraluminal accumulation of cell debris and heterophiles (H&E X66)

DISCUSSION

Cyclophosphamide (CP) is an immunosuppressive drug, which is commonly used in immunological experiments (Awaad et al, 1978, 2000a, Nakamura et al., 1987 and Al-Afaleq and Jones, 1991).

In the present investigation; experimental chickens inoculated over 3 days with CP showed complete suppression of humoral immune response during 14 days PSRBCsI with developing of a low haemagglutinating (HA) antibody titer (0.5 geometric mean) that appeared only at 21st day post immunization (Table 1 and Fig.1A). These findings demonstrate the effect produced by CP as a medication used to produce chemical bursectomy as described by Warner et al. (1969). Lerman and Weidanz (1970) have already established the effect of CP as a depressor of the humoral response. CP dramatically affected cell mediated immunity resulted in a lower lymphocytic transformation stimulation indices during the entire period of the experiment (21 days) as compared with non-immunosuppressed chickens (Table 1 and Fig. 1B). Glick (1971) and Higara et al. (1976) recorded that CP is primarily a B-cell suppressor, however; it also produces transient T-cell deficiency. CP also induced a marked alteration in the histomorphologic features of major lymphoid

organs (bursa of Fabricius, thymus gland and spleen). However the effect on the bursa of Fabricius was much more severe and progressive than its effect on the thymus or spleen, particularly the latter which showed insignificant changes. Bursal changes ranged from almost complete depletion of lymphocytes in bursal follicles to markedly atrophied follicles which were widely separated by fibrous interfollicular stroma with only reticular cells remaining or even vacuolated follicles. At 21 days post CP treatment, bursa of Fabricius showed few severely atrophied lymphoid follicles widely separated by thickened edematous interfollicular stroma. In CP immunosuppressed chickens lowered bursa / body weight (B / B.W.), spleen / body weight (Sp. / B.W.) and thymus / body weight (T / B.W.) indices were recorded. Moreover, severe decrease in serum Tf, IgG and IgM during the entire 21 days post CP treatment were observed as compared with the non-immunosuppressed ones (Table 4).

These findings are completely accord with that reported by Elmubarak et al. (1981) and Awaad et al (2000 a).

HA test was adopted for detection of antibody titers expressed in geometric means PSRBCsI. Detectable HA titers could be determined 3 days post immunization in the non-immunosuppressed control group and maintained till the end of the

experiment (21 days). An increase in geometric mean of HA titers appeared only at 14 and 21 days PSRBCsI at a low-level (0.5) in vitamin E immunostimulated group, while Propiobacterium granulosum treated group started to record HA geometric means from day 7 (1.8) and reached highest level at 21 days (5.1) post immunization (Table 1).

For assaying the immunomodulatory effect of the studied immunostimulators on cellular immune response; lymphocytic blastogenesis measured by MTT revealed statistical significant increase in chickens received IM-104® or vitamin E, on detection at 10 and 14 days over their non-immunostimulated control group (Table 1).

The FCR in Propiobacterium granulosum immunostimulated group was 32 points lower than that of the control group. However, generally speaking the obtained FCR reflects the bad quality of the used commercial ration.

An alteration in major lymphoid organs / body weight indices were recorded with statistic significant increase in B / B. Wt. index at 14 and 21 days and in S / B. Wt. index at 21 days in Propiobacterium granulosum treated group post immunization and in B / B. Wt. Index in vitamin E treated group at 21 days post immunization (table 1).

Histomorphological features of cyclophosphamid

treated chickens gave similar results with those described by Awaad et al. (2000 a). On the other hand; those of experimented immunopotentiators completely paralleled with results of the immunoassay. By the day 7 immunopotentiated birds showed that the activated lymphoblast cells began to appear in some bursal follicles and the medulla and cortex of the thymic lobule. Fourteen days post immunization these birds showed significant increase in number of activated lymphoblast cells and many lymphocytes appeared in some follicles. These changes were more obvious in IM-104 treated chickens. The spleen and thymus of such birds were nearly normal; whereas those of CP treated chickens showed moderate depletion of lymphocytes. Twenty-one days post immunization the bursae of vitamin E or Propiobacterium granulosum treated birds revealed an increasing number of lymphocytes in many follicles particularly in IM-104 treated group.

For overall judgement on immunomodulation of studied preparation in immunosuppressed birds; a bioassay was carried out. Challenge with E.coli O 78 was undertaken 7 days post course of administration of immunostimulators. Challenge with E.coli O 78 resulted in 84.4 % and 69.9 % protection for Propiobacterium granulosum and vitamin E treated groups respectively as compared with 48.9 % in non-immunostimulated CP immunosuppressed chicken group (Table 3). This means

that administration of IM-104 or vitamin E could improve the immunosuppression and increased the protection against infection.

Awaad et al. (1999 and 2000 b) proved the immunopotentiality of weak organic acids for cyclophosphamide treated and untreated chickens using both immunoassay and bioassay as criteria.

Brander et al. (1991) reported that immunomodulators administered simultaneously with antigens might potentiate specific immune response, particularly to vaccines. They concluded that immunostimulants, which promote immune function after antigenic exposure, could be used for treating diseases caused by infectious agents for which no satisfactory vaccine or treatment is available.

Electrophoretic analysis in PAGE revealed significant increase in serum Tf and immunoglobulins (IgG and IgM) in CP treated chickens that immunopotentialized with either IM-104 or vitamin E over their non immunostimulated control group during the entire period of the experiment. This increase was much higher in *Propionibacterium granulosum* treated group. Morgan (1974) reported that Tf plays a vital and central role in iron metabolism and has a second important function that of participating in the body's defense mechanism against infections. Aforementioned results of lymphocytic transformation completely confirm the report of Tormey et al. (1972) who mentioned

that lymphocytes may have an iron requirement for transformation, and the function of Tf could be the iron supply which enhances the growth of lymphocytes in response to antigen. The increase in immunoglobulins in the electrophoretic study correlates well with the results of haemagglutination test.

REFERENCES

- Al-Afaleq, A and Jones, R. C. (1991). A trypsin-sensitive avian reovirus: isolation and experimental infection of poult and chicks. *Avian pathology* 20, 5-16.
- Anon (1971). *Methods for examining poultry biologics and for identifying pathogens*. Nat. Acad. Sciences, Washington, D.C.
- Awaad, M. H. H., K. Graf, H. D. Schmatz and H. Krauss (1978). Electrophoretic changes in serum transferrin and gammaglobulins following *Rickettsia moseri* infection in cyclophosphamide treated mice. *Zbl.Vet. Med. B*, 25, 586-595.
- Awaad, M. H. H., F. E. Saad, M. A. Afify, O. A. Elshazly and H. F. El-Menyawi (1999). Immunomodulation of organic acids in chickens. *SCVMJ*, II, 1: 103-114.
- Awaad, M. H. H., F. E. Saad, O. A. Elshazly, M. A. Afify, S. A. Zouelfkar and Hala F. El Menyawi (2000 a). Immunomodulation of acidifiers in cyclophosphamide treated chickens. *Vet. Med Journal. Giza*, 48, No. 1, 145-160.
- Awaad, M. H. H. M., O. A. Elshazly, S. Zouelfakar, A. Afify, and Iman, B. Shaheed (2000 b). Immunomodulatory

- properties of inactivated probiobacterium granulosum (IM-104). 1: In nonimmunosuppressed chickens. Egypt. Vet. Med. Assoc. (In press).
- Boyum, A. (1968). Isolation of mononuclear cells and granulocytes from human blood. *Scan. J. Clin. Lab. Invest.* 21: 77-89.
- Brander, G. C., D. M. Pugh, R. J. Bywater and W. L. Jenkins (1991). *Veterinary Applied Pharmacology and Therapeutics*. 5th. Ed. Bailliere Tindall 24-28 Oval Road, London NW1 7DX, p. 401.
- Carpenter C. R., S. R. Arnold, and H. R. Bose, JR. (1978). Suppression of mitogen-stimulated blastogenic response during reticuloendotheliosis virus-induced tumorigenesis: Investigation into the mechanism of action of the suppressor. *J. Immunol.* 120: 1313-1320.
- Charles, R., Carpenter, A. B., Henry, R. and Bose, J. R. (1978). Suppression of the mitogen-stimulated blastogenic response during reticuloendotheliosis virus induced tumorigenesis. *J. Immunol.* 120, (4): 1313-1320.
- Cochran, W.J. and Cox, G.M. (1960). *Experimental designs*. 2nd Ed., Constock Publishing Association, Ithaca, N.Y.
- Confer, A. W., W. T. Springer, S. M. Shane, and J.F. Donovan. (1981). Sequential mitogen stimulation of peripheral blood lymphocytes from chickens inoculated with infectious bursal disease virus. *Am. J. Vet. Res.* 42: 2109-2113.
- Elmubarak, A. K., J. M. Sharma, L. F. Lee and V. L. Sanger (1981). Suppression of immunologic function and degeneration of lymphoid organs in cyclophosphamide-treated turkeys. *Am. Vet. Res.*, 42, (12): 2122-2128.
- Gern, H., H. Krause, V. Enzmann, and K. Drobler, (1994). An improved MTT assay using electron coupling agent menadione, *J. Immunol. Meth.* 168: 253-256.
- Glick, B. (1971). Morphological changes and humoral immunity in cyclophosphamide-treated chicks. *Transplantation.* 11: 443-439.
- Hanks, J. H. and J. H. Wallace (1958). Determination of cell viability. *Proc. Soc. Exp. Biol. Med.* 98: 183-192.
- Higara, T., Sugimura, M. and Kudo, N. (1976). Effect of cyclophosphamide on the thymus and the bursa of Fabricius in chickens. *Japanese Journal of Veterinary Research.* 24: 87-98.
- Lerman, S. P., and Weidanz (1970). The effect of cyclophosphamide on the ontogeny of the humoral immune response in chickens. *J. Immunol.* 105: 614-619.
- Lucy, F.L. (1984). Proliferation response of chicken T and B-lymphocytes to mitogens. *Chemical regulation of immunity in Veterinary Medicine* 15: 44-52.
- Maurer, H. R. (1971). *Disc electrophoresis and related techniques of Polyacrylamide gel electrophoresis*. Walter de Gruyter, Berlin, New York.
- Morgan, E. H. (1974). Transferrin and transferrin iron. In: *Iron in Biochemistry and Medicine*. Jacobs and Warwood (1974). Academic Press London and New York, p.29.
- Nakamura, K., Y. Imada and F. Abe (1987). Effect of Cyclophosphamide on infections produced by *Escherichia coli* of high and low virulence in chickens. *Avian Pathology*, 16: 237-252.
- Sharma, J.M. Dohms, J.E. and Metz, A.L. (1989). Comparative pathogenesis of serotype 1 and variant serotype 1

- of infectious bursal disease virus and their effect on specific pathogen free chickens. *Avian Dis.* 33: 112-124.
- Snedcor (1956). *Statistical Methods*. 4th. Ed. Iowa State Univ. Press, Ames Iowa, USA.
- Tormey, D. C., R. C. Imrie, and G. C. Mueller (1972). Identification of transferrin as a lymphocyte growth promoter in human serum. *Expl. Cell. Res.*, 74, 163.
- Warner, N. L., W. Uhr, G. J. Thorbecke, and Z. Ovary (1969). Immunoglobulins, antibodies and the bursa of Fabricius: induction of gamaglobulinemia and the loss of all antibodies forming capacity by hormonal bursectomy. *J. Immunol.* 103: 1317-1330.