

Potential Clinical Role of Propolis in Treatment of Clinical Ovine and Caprine Listeriosis

Ismael, A.B. *, Masoud, El-S. El-S. ** and El-Nabtity, S. M. ***

*Dept. of Animal Medicine, Fac. Vet. Med., Zagazig University

**Animal Health Research Institute, Zagazig branch

***Dept. of Pharmacology, Fac. Vet. Med., Zagazig University

Received: 07/10/2009

Accepted: 08/12/2009

SUMMARY

In this study, we have tested the possible use of propolis, one of the few natural remedies that exhibits potential therapeutics properties, in combination with some antibacterial drugs for treatment of clinical ovine and caprine listeriosis that was described and diagnosed. Three private sheep flocks of 485 sheep and 2 private goat flocks of 275 goats were carefully clinically examined after appearance of different forms of suspected clinical listeriosis. The clinical diagnosis was confirmed by histopathological and bacteriological examinations. The infected sheep and goats were divided into groups based on the clinical form of listeriosis for field treatment.

Results: In ovine listeriosis, 73 out of 485 sheep were affected with 15.05 % overall morbidity and 10.96% case fatality rates, respectively. In caprine listeriosis, 55 out of 275 goats were affected with 20% overall

morbidity rate and no case fatality rate. Encephalitic listeriosis was more prevalent among sheep while listerial abortion and septicaemic listeriosis were more prevalent among goats. Histopathologically, the brain tissues showed extensive perivascular mononuclear cuffing with microabscesses. Bacteriologically, *L. monocytogenes* was isolated from (31.09%) and (26.98%) of collected samples in sheep and goats respectively. The field treatment revealed that the affected sheep and goats treated with biopropolis alone or with antibiotic combination regimen reduced the overall severity of listeriosis better than those treated with antibiotic alone (ampicillin or cefotaxime alone) or cefotaxime alternative with gentamicin and trimethoprim-sulphadimethoxine combination. Combined treatment with ampicillin-biopropolis dosage regimen was found to be the most effective.

Keywords: Clinical Ovine and Caprine Listeriosis; *Listeria monocytogenes*; Propolis

INTRODUCTION

Listeriosis is an infectious disease affecting a wide range of mammals, including ruminants, monogastric animals and humans. The disease is caused by a facultative intracellular Gram positive aerobic nonspore forming coccobacillus bacterial pathogen, *Listeria monocytogenes*, which has become a multifaceted model and remains a nagging public health hazard that now ranks among the most documented pathogens (Cossart, 2007). Thirteen serovars (1/2a, 1/2b, 1/2c, 3a, 3b, 3c, 4a, 4ab, 4b, 4c, 4d, 4e and 7) have been reported for *L. monocytogenes* and this serotyping is of limited value in epidemiological investigations, as only few serovars (1/2a, 1/2b, 3 and 4b) are most commonly isolated in farm animals (Low and Donachie, 1997).

Listeriosis may be manifested in sheep and goats by three main distinct clinical syndromes, encephalitis, abortion and septicaemia (Low et al., 1993; Scott, 2007 and Brugère-Picoux, 2008). On the farm level, there is a direct link between silage feeding and infection so; feeding of poor-quality silage seems to be a key factor in disease transmission that is more frequent in winter and early spring (Vazquez-Boland et al., 1992).

Bacteriological testing and histological examination are the classical methods used for the laboratory diagnosis of listeriosis in animal specimens. These procedures are

usually considered the "gold standard" to which other methods are compared (Walker, 1999).

To date, *Listeria* infections are almost always treated with antibiotics, but antibiotic resistance in *L. monocytogenes* is being reported with increasing frequency for both food and clinical isolates (Conter et al., 2009; Srinivasan, et al., 2005). This is highlighting the need for novel antimicrobial agents to overcome the antibiotic resistance.

Propolis (Bee-glue) has attracted much attention in recent years as a useful natural substance applied in medicine and has been found to be a promising source of potential therapeutics due to its pharmacological and biological values as antibacterial (Bankova, et al., 1996; Mirzoeva, et al. 1997), antioxidant, (Ahn, et al., 2007), anti-inflammatory and analgesic (Paulino, et al. 2008), and antipyretic (Dobrowolski et al., 1991). The presence of a large number of flavonoids, aromatic acids and phenolics compounds is responsible for the most biological and therapeutic activities of propolis (Bankova, et al, 1987). The synergistic effect of propolis with some antibiotics was proved (Stepanovic, et al., 2003). Propolis is a complex brownish resinous, strongly adhesive natural substance, collected by honeybees from buds and leaves of trees and plants, mixed with pollen as well as enzymes secreted by bees to seal the walls and entrance of the hive and

contributes to protect the colony against different pathogens (Burdock, 1998).

To the best of our knowledge, there are no previous studies reporting the effects of propolis on clinical listeriosis in the field. The aim of the current study is firstly, to describe the problem of clinical listeriosis in sheep and goats and throw a spotlight on its confirmatory diagnosis. Then, to evaluate the effects of six different treatment combinations, propolis alone, ampicillin alone, ampicillin- biopropolis combination regimen, cefotaxime alone, cefotaxime-biopropolis combination regimen or cefotaxime alternative with gentamicin and trimethoprim-sulphadimethoxine combination., to find out whether propolis could be an alternative or an adjunctive treatment, in clinical ovine and caprine listeriosis.

MATERIAL AND METHODS

Animals and clinical examination: The present study was carried out on 3 private sheep flocks of 485 sheep and 2 private goat flocks of 275 goats, of different ages and sexes. Seventy three sheep and 55 goats showed different forms of suspected clinical listeriosis (Table 1). The affected sheep and goats among examined flocks were closely monitored and subjected to thorough clinical examination in the mornings and evenings for 5 weeks to assess day to day changes before

and after treatment. Detailed past and immediate history and management practices were recorded.

Samples

1. Samples for bacterial isolation: Brainstems, faecal samples, silage, spoiled hay, vaginal discharge swabs, livers of aborted and stillborn lambs and kids and blood on EDTA were collected aseptically for bacterial isolation either pre- or post-treatment. Handling, transporting and storing of collected samples were made at refrigeration temperatures (4°C) until processed for microbiological analysis.

2. Samples for histopathological examination: Brain and liver tissues were collected in neutral 10% buffered formalin for histopathology.

Histopathological examination: Post-mortem examination (PM) was applied on 8 recently dead animals from encephalitis as well as all aborted and stillborn lambs and kids. Tissues in formalin were processed and thin sections were prepared and stained with Haematoxylin and Eosin stain (H & E) then were assessed microscopically (Amagliani et al., 2006).

Bacteriological investigation: It was performed using the technique described by (Erdogan et al., 2002).

Antimicrobial susceptibility test: It was carried out according to (Branka et al., 2006) by means of disc diffusion test.

Field treatment and Synergy trials: The affected sheep and goats were divided into

groups based on the clinical form of listeriosis (Tables 3 and 5), five groups for each form in sheep and 6 groups in goats. Group I in each form was intramuscularly injected with ampicillin alone (CID, Egypt); 10 mg/Kg body weight (B.W.) (Amagliani et al., 2006), twice daily for 14 successive days. Group II in each form was intramuscularly injected with ampicillin; 10 mg/Kg B.W. twice daily for 7 successive days followed by biopropolis (Sigma, Egypt); 13 mg/kg B.W. once daily, per Os for the next 7 successive days. Group III in each form was intramuscularly injected with cefotaxime alone (PRIMAVET, Egypt); 13 mg/kg B.W. twice daily (Sharma and Srivastava, 2006) for 14 successive days. Group IV in each form was intramuscularly injected with cefotaxime; 13 mg/kg B.W. twice daily for 7 successive days followed by biopropolis; (Sigma, Egypt); 13 mg/kg B.W. once daily, per Os for the next 7 successive days. Group V in each form treated with the intravenous administration, in electrolytes, of cefotaxime, 1.5 ml/10 kg B.W for 7 successive days alternative with gentamicin and trimethoprim-sulphadimethoxine combination (GENTAPRIM, United Biopharm, Egypt) 1ml/10 kg B.W. for the next 7 successive days (Ismael et al., 2008). Group VI of goats suffered from listerial abortion and gastrointestinal listeriosis was treated with biopropolis alone (Sigma, Egypt); 13 mg/kg B.W. once daily, per Os for 14 successive days. All treated sheep and goats were

examined daily for monitoring any clinical improvement. Vaginal smears, faecal samples and/or rectal swabs were collected weekly up to one month from aborted cases for bacteriological examination to ensure the complete recovery. All predisposing factors were monitored and controlled.

Statistical analysis: The Statistical Products and Service Solutions (SPSS) program was used for all analysis. Comparisons among groups were tested using the Student's t-tests. A difference was considered to be significant at $P < 0.05$.

RESULTS

Clinical findings:

1. In sheep: Out of 485 sheep in the three flocks, 73 were affected with 15.05 % overall morbidity and 10.96% case fatality rates (Table 1). The clinical listeriosis was observed on silage and spoiled hay-fed sheep during wintertime. Encephalitic listeriosis was more prevalent among sheep and was observed in 2 flocks (n=48). In early stage of encephalitic listeriosis, the animals started moving in circles with deviated head and neck (Fig. 1). In the late stages, eight sheep were unable to eat with drooling of saliva and presence of undigested food inside the mouth. Finally, the animal became recumbent, showing convulsions and paddling movements and inability to rise (Fig. 2). The course of this form varied from 2 to 7 days

after appearance of the first clinical finding(s).

Abortion in adult pregnant ewes (n=25) at late pregnancy was observed in one flock only. Blood-stained vaginal discharge was observed for several days after abortion accompanied with diarrhea and recumbency in some aborted ewes. Moreover there were 32 stillbirths lambs with fatal septicaemia. Septicaemia was also seen in seven aborted ewes.

2. **In goats:** Out of 275 goats in two flocks only, 55 were affected with 20% overall morbidity and without deaths. Listerial abortion and septicaemic listeriosis was more prevalent among goats, while encephalitic listeriosis was not observed in goat flocks (Table 1). This form was also observed on silage and spoiled hay-fed goat during the winter. Thirty three affected goats were aborted at late pregnancy with fatal septicaemia in 44 stillbirth's kids. Gastrointestinal listeriosis was also observed in some non-pregnant goats (n=22) in the form of diarrhoea.

Post-mortem findings: There were no gross lesions in the brain or any other part of eight sheep recently died from encephalitis, while multiple necrotic foci in liver and spleen were observed in all aborted and stillborn lambs and kids.

Microscopical examination, the brain tissues particularly medulla oblongata and pons showed extensive perivascular

mononuclear cuffing and single or multiple microabscesses (Figs. 3 and 4).

Bacteriological examination:-

1. **In sheep:** Bacteriological examination using a three-stage isolation technique revealed that *L. monocytogenes* was isolated from 6 out of 8 brainstems, (11/73) faecal samples, (2/3) silage and spoiled hay, (19/25) vaginal discharge and (13/32) livers of aborted and stillborn lambs, with a total 51 (31.09 %) isolates from all collected samples (Table 2). No *Listeria* was isolated from blood. It was interesting to note that no isolates were determined by direct plating before cold enrichment while all the isolates were determined after different periods of cold enrichment at 4°C depending upon the clinical forms of listeriosis.

2. **In goats:** Bacteriological examination using a three-stage isolation technique revealed that *L. monocytogenes* was isolated from 8 out of 55 faecal samples, (2/2) silage and spoiled hay, (23/33) vaginal discharge and (18/44) livers of aborted and stillborn kids, with a total 51 (26.98%) isolates from all collected samples (Table 2).

***In vitro*, antimicrobial susceptibility test:** The field isolates of *L. monocytogenes* exhibited, *in vitro*, high susceptibility towards ampicillin, propolis, cefotaxime, penicillin, gentamicin, amoxicillin, tetracycline, trimethoprim-sulphamethoxazole and intermediary susceptibility to enrofloxacin and streptomycin.

Field treatment: It revealed that the affected sheep and goats treated with biopropolis alone or with antibiotic combination regimen significantly reduced the overall severity of listeriosis better than those treated with antibiotic alone (ampicillin alone or cefotaxime alone) or cefotaxime alternative

with gentamicin and trimethoprim-sulphadimethoxine combination (Table 3-5). Treatment with ampicillin- biopropolis combination regimen seems to be the most effective, but biopropolis alone or cefotaxime combined with biopropolis may offer a good alternative treatment.

Table 1: Epidemiological data and clinical findings of outbreaks of ovine and caprine listeriosis

Items	Clinical forms of listeriosis			Morbidity rate	Case fatality rate
	Encephalitic	Listerial abortion ^a	GI listeriosis ^b		
Ovine listeriosis	48/485 (9.89%)	25/485 (5.15%)	- 0%	73/485 (15.05%)	8/73 (10.96%)
Caprine listeriosis	- (0%)	33/275 (12%)	22/275 (8%)	55/275 (20%) ^b	- 0%

^a Some aborted ewes (n=7) showed septicaemic listeriosis. Moreover there were 32 stillbirths' lambs and 44 stillbirths' kids with fatal septicaemia. ^b GI listeriosis means gastrointestinal listeriosis which observed in some non-pregnant goats in the form of diarrhoea.

Table 2: Results of bacteriological examination of the different samples for ovine and caprine listeriosis

Type of samples	Ovine listeriosis ^a	Caprine listeriosis ^a
Brainstems	6/8	-
Faecal samples	11/73	8/55
Silage and spoiled hay	2/3	2/2
Vaginal discharge	19/25	23/33
Livers of aborted and stillbirth lambs or kids	13/32	18/44
Blood	0/23	0/55
Total	51/164 (31.09%)	51/189 (26.98%)

^a *Listeria monocytogenes* positive samples/No. of samples

Table 3 Results of field treatment for ovine listerial abortion

Group	No.	Therapeutic regimen	Clinical improvement	Bacteriological examination ^c
Group I	5	Ampicillin alone for 14 successive days	2/5 (40.0%) ^a	3 positive ^a
Group II	5	Ampicillin for 7 successive days combined with biopropolis for the next 7 successive days	5/5 (100%) ^b	0 positive ^b
Group III	5	Cefotaxime alone for 14 successive days	2/5 (40.0%) ^a	3 positive ^a
Group IV	5	Cefotaxime for 7 successive days combined with biopropolis for the next 7 successive days	4/5 (80.0%) ^b	1 positive ^b
Group V	5	Cefotaxime for 7 successive days then gentamicin & trimethoprim-sulphadimethoxine for the next 7 successive days	3/5 (60.0%) ^a	2 positive ^a

^a : Significant difference with ^b ($P \leq 0.01$) in the same column and non significant to that marked with ^a. ^b : Significant ($P \leq 0.01$) to that marked Bankova with ^a in the same column and non significant to that marked with ^b. ^c : Bacteriological examination was done in collected vaginal smears, faecal samples and/or rectal swabs, 2 weeks post-treatment.

Table 4: Results of field treatment for caprine listerial abortion and gastrointestinal listeriosis

Group	No.	Therapeutic regimen	Clinical improvement	Bacteriological examination ^c
Group I	9	Ampicillin alone for 14 successive days	3/9 (33.3%) ^a	5 positive ^a
Group II	9	Ampicillin for 7 successive days combined with biopropolis for the next 7 successive days	8/9 (88.9%) ^b	0 positive ^b
Group III	9	Cefotaxime alone for 14 successive days	3/9 (33.3%) ^a	6 positive ^a
Group IV	9	Cefotaxime for 7 successive days combined with biopropolis for the next 7 successive days	7/9 (77.8%) ^b	2 positive ^b
Group V	9	Cefotaxime for 7 successive days then gentamicin & trimethoprim-Sulphadimethoxine for the next 7 successive days	4/9 (44.4%) ^a	4 positive ^a
Group VI	9	Biopropolis alone for 14 successive days (88.9%) ^b	8/9	2 positive ^b

^a : Significant difference with ^b ($P \leq 0.01$) in the same column and non significant to that marked with ^a. ^b : Significant ($P \leq 0.01$) to that marked with ^a in the same column and non significant to that marked with ^b. ^c : Bacteriological examination was done in collected vaginal smears, faecal samples and/or rectal swabs, 2 weeks post-treatment.

Table 5: Results of field treatment for ovine encephalitic listeriosis

Group	No.	Therapeutic regimen	Clinical	Bacteriological
			improvement	examination ^c
Group I	8	Ampicillin alone for 14 successive days	2/8 (25%) ^a	1 positive ^a
Group II	8	Ampicillin for 7 successive days combined with biopropolis for the next 7 successive days	7/8 (87.5%) ^b	0 positive ^b
Group III	8	Cefotaxime alone for 14 successive days	2/8 (25.0%) ^a	1 positive ^a
Group IV	8	Cefotaxime for 7 successive days combined with biopropolis for the next 7 successive days	6/8 (75.0%) ^b	1 positive ^a
Group V	8	Cefotaxime for 7 successive days then gentamicin & trimethoprim-Sulphadimethoxine for the next 7 successive days	3/8 (37.5%) ^a	1 positive ^a

^a Significant difference with ^b ($P \leq 0.01$) in the same column and non significant to that marked with ^a. ^b Significant ($P \leq 0.01$) to that marked with ^a in the same column and non significant to that marked with ^b. ^c Bacteriological examination was done in collected faecal samples and/or rectal swabs, 2 weeks post-treatment.



Fig. 1: Sheep in early stage of encephalitic listeriosis, the animal started moving in circles with deviated head and neck.

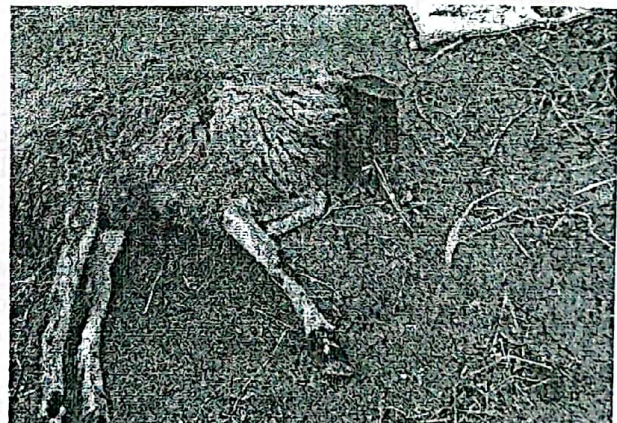

Fig. 2: Sheep in late stage of encephalitic listeriosis, the animal was unable to eat due to facial and tongue paralysis and became recumbent.




Fig. 3: Section of the sheep brain showing microabscess (H&E. 150).

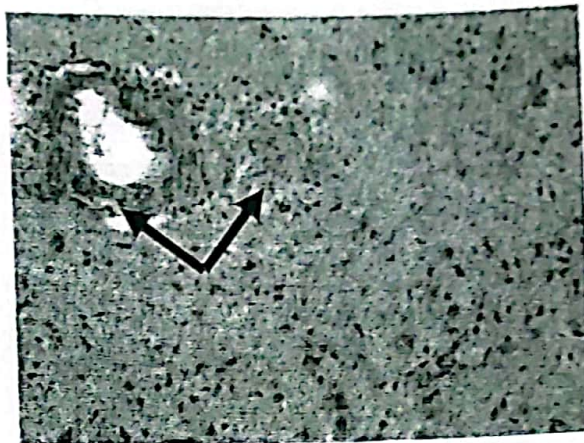


Fig. 4: Section of the sheep brain showing perivascular cuffs with microabscess (H&E. 150).

DISCUSSION

Concerning the epidemiological data and clinical findings, clinical listeriosis was shown on poorly fermented silage and spoiled hay-fed sheep and goats and the risk for silage contamination is higher when it contains soil. Our results are in agreement with those reported by (Vazquez-Boland et al., 1992; Low and Donachie, 1997).

Encephalitic listeriosis was more prevalent among sheep and was seen in 2 flocks while listerial abortion and septicaemic listeriosis were recorded in one sheep flock only. In the three flocks, 73 sheep were affected out of 485 animals with overall morbidity and case fatality rates of 15.05 % and 10.96%, respectively. These data are

approximately similar to the results of (Gitter et al., 1986 and Scott, 2007), who showed that encephalitic listeriosis was more prevalent among ruminants, especially sheep, with an attack rate of approximately 10–12% and a mortality rate of approximately 5–10%. The explanation for the rarity with which encephalitis and abortion are recorded in the same flock and why encephalitis occurs more frequently in many silage-fed animals was shown in other studies (Low and Donachie, 1991; Low and Donachie, 1997) who reported that during silage feeding, subclinical infections commonly occur and those animals became protected against the septicaemic and abortion forms of listeriosis. Nevertheless, these responses may not be wholly effective in protecting against encephalitis. The clinical findings of encephalitic listeriosis might be

resulted from trigeminal nerve infection consequent to abrasions of the buccal mucosa with feed or infection of teeth cavities (Kumar et al., 2007 and Oevermann, et al., 2008). Another study (Braun et al., 2002) revealed that the unilateral or bilateral cranial nerve deficits are responsible for the main clinical findings of encephalitic listeriosis. In the advanced stages of illness, diseased animal became recumbent, showing convulsions and paddling movements (Scott, 2007 and Brugère-Picoux, 2008).

The listerial abortion and septicaemic listeriosis were more prevalent among goats and were observed in the 2 flocks under study while encephalitic listeriosis was not observed (Table 1). The high case fatality rate in sheep (10.96%) and no case fatality rate in goats (0%) might be due to different feeding habits of grazing and browsing in sheep and goats, respectively (Kumar et al., 2007). The occurrence of listerial abortion and septicaemic listeriosis in both goats and sheep might be attributed to infection with *L. monocytogenes* at all stages of pregnancy, which can result in placentitis, metritis, fetal infection and death, abortion, stillbirths, neonatal deaths or septicaemia, and possibly viable carriers (Scott, 2007). Blood-stained vaginal discharge was observed for several days after abortion accompanied with diarrhea and recumbency in some animals. Gastrointestinal listeriosis was observed in some non-pregnant goats in the form of

diarrhoea and this form of the disease can be observed with abortion. These findings are in coincidence with that reported by (Low and Donachie, 1997 and Brugère-Picoux, 2008).

Microscopical examination of the brain tissues showed extensive perivascular mononuclear cuffing and single or multiple microabscesses.. This picture resembles that reported by (Amagliani et al., 2006; Kumar et al., 2007). Although isolation of *L. monocytogenes* remains important for diagnosis of the disease, the use of histopathology increases overall sensitivity of diagnosis (Brugère-Picoux, 2008).

The relative low number of field isolates (Table 2) compared to the clinical cases might be attributed to the very small quantities of *L. monocytogenes* in the clinical samples (Low and Donachie, 1997 and Branka et al., 2006). The limit of detection is often too low and *L. monocytogenes* is outgrown when heavily contaminated samples such as faeces are examined. This gave rise to a need for an enrichment step prior to plating. It was indicated that the holding of clinical samples at refrigeration temperature without any liquid media for long duration was the better application and this confirmed the previous findings of (Erdogan et al., 2002).

The present application study provides for the first time evidence for a possible clinical role of propolis in the treatment of clinical ovine and caprine listeriosis either alone (in goats) or in combination with certain

antibiotics (Table 3). Ampicillin and gentamicin have been reported as the treatment of choice for listeriosis (Low and Donachie, 1997), but other antibiotics can also be used: procaine penicillin or tetracycline. The association of trimethoprim and sulphamethoxazole is considered to be a second-choice therapy. Antibiotic resistance in *L. monocytogenes* is being reported with increasing frequency for both food and clinical isolates (Conter et al., 2009). Acquired antimicrobial resistance in clinical strains has been found with a significant frequency in animal isolates (Srinivasan, et al., 2005). This is highlighting the need for novel antimicrobial agents as propolis. Although the synergistic action of propolis with antibiotics was previously assayed *in vitro* against Gram-positive bacteria, including *L. monocytogenes* (Mirzoeva et al. 1997 and Stepanovic, et al., 2003), no field observations of synergism are reported against *L. monocytogenes*. Our results demonstrated that the affected sheep and goats treated with ampicillin- biopropolis combination regimen reduced the overall severity of listeriosis better than those treated with ampicillin alone or cefotaxime alone or cefotaxime combined with biopropolis or cefotaxime alternative with gentamicin and trimethoprim-sulphadimethoxine combination (Tables 3 - 5). The results of synergistic action of propolis with antibiotics demonstrated potential of propolis to enhance antibiotic action and could

allow the reduction in the dose of selected antimicrobials and potentiation of the antimicrobial therapy. It has been suggested that the therapeutic activities of propolis depend mainly on the presence of flavonoids that enhance hematopoietic and immune system (Wleklik et al., 1997 and Oršolic and Bašić, 2003), also its activity as oxygen radical scavengers (Zeng, et al., 1997). Moreover, the propolis affects the cytoplasmic membrane and inhibits bacterial motility and enzyme activity (Mirzoeva, et al. 1997). The antibacterial activity of propolis is bacteriostatic and can be bactericidal in high concentrations (Mirzoeva, et al., 1997). Acute and chronic toxicity studies on propolis are still inconclusive (Burdock, 1998). The results of antimicrobial tests are unambiguous proofs, that in spite of the great difference in the chemical composition of propolis of different geographical origins and collecting bee races, all of them exhibit significant antimicrobial activities (Bankova, 2005). The analgesic and anti-inflammatory effects of propolis, *in vivo* & *in vitro*, might be attributed to its content of Artepillin C at low concentrations (Paulino, et al. 2008). This effect is important in clinical listeriosis.

In conclusion, the propolis has a potential clinical role in the treatment of ovine and caprine listeriosis particularly in combination with ampicillin. The results could motivate a higher medical interest and further laboratory and clinical trials for

evaluating the use of propolis for prophylaxis or treatment of other important bacterial infections.

Acknowledgement

The authors are thankful to Professor Abou-El-Fetouh, M. S, Dept. of Pathology, Fac. Vet. Med., Zagazig University, Egypt for skillful assistance in histopathological examination.

REFERENCES

- Ahn, M-R., Kumazawa, S., Usui, Y., Nakamura, J., Matsuka, M., Zhu, F. and Nakayama, T., 2007. Antioxidant activity and constituents of propolis collected in various areas of China. *Food Chem.* 101, 1383-1392.
- Amagliani, G., Giammarini, C., Omiccioli, E., Merati, E.G., Pezzotti, G., Filippini, G., Brandi, G. and Magnani, M., 2006. A combination of diagnostic tools for rapid screening of ovine listeriosis. *Res. Vet. Sci.* 81, 185-189.
- Banková V., 2005. Recent trends and important developments in propolis research. *C.A.M.* 2, 29-32.
- Bankova, V. S., Dyulgerov, A., Popov, S. and Marekov, N., 1987. A GC/MS study of propolis phenolic constituents. *Z. Naturforsch. Teil 42C*, 147-151.
- Bankova, V., Marcucci, M. C., Simova, S., Nikolova, N., Kujumgiev, A. and Popov, S., 1996. Antibacterial diterpenic acids from Brazilian propolis. *Z. Naturforsch. C* 51, 277-280.
- Branka, V., Dubravka, M. and Bugarski, D., 2006. Isolation of *Listeria monocytogenes* in neural forms of listeriosis and abortions in ruminants. *Acta Veterinaria (Beograd)* 56, 343-351.
- Braun, U., Stehle, C. and Ehrensperger, F., 2002. Clinical findings and treatment of listeriosis in 67 sheep and goats. *Vet. Rec.* 150, 38-42.
- Brugère-Picoux, J., 2008. Ovine listeriosis. *Small Ruminant Research*; 76, 12-20.
- Burdock, G. A., 1998. Review of the biological properties and toxicity of bee propolis (propolis). *Food Chem. Toxicol.* 36, 347-363.
- Conter, M., Paludi, D., Zanardi, E., Ghidini, S., Vergara, A. and Ianieri, A., 2009. Characterization of antimicrobial resistance of food-borne *Listeria monocytogenes*. *Int. J. Food Microbiol.* 128, 497-500.
- Cossart, P., 2007. Listeriology (1926-2007): the rise of a model pathogen. *Microb. Infect.* 9, 1143-1146.
- Dobrowolski, J. W., Vohora, S. B., Sharma, K., Shah, S. A., Naqvi, S. A. H. and Dandiya, P. C. 1991. Antibacterial, antifungal, antiamebic, antiinflammatory and antipyretic studies on propolis bee products. *J. Ethnopharmacol.* 35, 77-82.
- Erdogan, H. M., Cripps, P. J. and Morgan, K. L., 2002. Optimization of a culture technique for the isolation of *Listeria monocytogenes* from faecal samples. *J. Vet. Med. B* 49, 502-506.
- Gitter, M., Stebbings, R.S., Morris, J.A., Hannam, D. and Harris, C., 1986. Relationship between ovine listeriosis and silage feeding. *Vet. Rec.* 118, 207-208.
- Ismael, A. B., Abuzeid, N., Masoud, E. A. and Abou-El-Fetouh, M. S., 2008. Clinical Ovine Listeriosis, its Diagnosis and Treatment. 9th Vet. Med. Zag. Conference (20-22 August 2008) Port-Said, Egypt, pp:301-309.
- Kumar, H. Singh, B.B., Bal, M.S., Kaur, K., Singh, R., Sidhu, P.K. and Sandhu, K.S., 2007. Pathological and epidemiological investigations into listerial encephalitis in sheep. *Small Ruminant Res.* 71, 293-297.
- Low, J. C. and Donachie, W., 1991. Clinical and serum antibody responses of lambs to

- infection by *Listeria monocytogenes*. Res. Vet. Sci. 51, 185-192.
- Low, J.C. and Donachie, W.A., 1997. A review of *Listeria monocytogenes* and listeriosis, Vet. J. 153, 9-29.
- Low, J.C., Wright, F., McLauchlin, J. and Donachie, W., 1993. Serotyping and distribution of listeria isolates from cases of ovine listeriosis. Vet. Rec. 133, 165-166.
- Mirzoeva, O.K., Grishanin, R.N., Colder, P.C., 1997. Antimicrobial action of propolis and some of its components: the effect on growth, membrane potential and motility of bacteria. Microbiol. Res. 152, 239-246.
- Oevermann, A., Botteron, C., Seuberlich, T., Nicolier, A., Friess, M., Doherr, M-G., Heim, D., Hilbe, M., Zimmer, K., Zurbriggen, A. and Vandeveld, M., 2008. Neuropathological survey of fallen stock: Active surveillance reveals high prevalence of encephalitic listeriosis in small ruminants. Vet. Microbiol. 130, 320-329.
- Oršolic, N. and Bašić, I. 2003. Immunomodulatory action of a water-soluble derivative of propolis, caffeic acid and caffeic acid phenethyl ester: nitric oxide and macrophage function. Mellifera 3, 56-64.
- Paulino, N., Abreu, S. R. L., Uto, Y., Koyama, D., Nagasawa, H., Hori, H., Dirsch, V. M., Vollmar, A. M., Scremin, A. and Bretz, W. A., 2008. Anti-inflammatory effects of a bioavailable compound, Artepillin C, in Brazilian propolis. Eur. J. Pharmacol. 587, 296-301.
- Scott P.R., 2007. Listeriosis. In: Aitken, I.D. (Ed.), Diseases of Sheep, Fourth edition, Blackwell publishing, Oxford, pp: 255-259.
- Sharma, S.K. and Srivastava, A.K., 2006. Subcutaneous pharmacokinetics and dosage regimen of cefotaxime in buffalo calves (*Bubalus bubalis*). J. Vet. Sci. 7, 119-122.
- Srinivasan, V., Nam, H.M., Nguyen, L.T., Tamilselvam, B., Murinda, S.E. and Oliver, S.P. 2005. Prevalence of antimicrobial resistance genes in *Listeria monocytogenes* isolated from dairy farms. Foodborne Pathog. Dis. 2, 201-211.
- Stepanovic, S., Antic, N., Dakic, I. and Svabic-Vlahovic, M., 2003. In vitro antimicrobial activity of propolis and synergism between propolis and antimicrobial drugs. Microbiol. Res. 158, 353-357.
- Vazquez-Boland, J. A., Dominguez, L., Blanco, M., Rocourt, J., Fernandez-Garayzabal, J. F., Gutierrez, C. B., Tascon R. I. and Rodriguez-Ferri E. F., 1992. Epidemiologic investigation of a silage associated epizootic of ovine listeric encephalitis, using a new listeria-selective enumeration medium and phage typing. Am. J. Vet. Res. 53, 368-371.
- Walker, R.L., 1999. Listeria. In: Hirsh, D.C., Zee, Y.C. (Eds.), Veterinary Microbiology. Blackwell Science, Malden, MA, USA, pp. 225-228.
- Wleklik, M., Zahorska, R. and Luczak, V., 1997. Interferon-inducing activity of flavonoids. Acta Microbiol. Pol. 32, 1141-1148.
- Zeng, L.H., Wu, J., Fung, B., Tong, J.H., Mickle, D. and Wu, T.W., 1997. Comparative protection against oxyradicals by three flavonoids on cultured endothelial cells. Biochem. Cell. Biol., 75, 717-720.

الدور الإكلينيكي الفعال للبروبوليس في علاج مرض الليستيريويزيس الإكلينيكي في الأغنام والماعز

علاء بسيوني إسماعيل ، السيد السعيد مسعود* ، سامح محمد مصطفى النبتي**

قسم طب الحيوان - كلية الطب البيطري - جامعة الزقازيق
*معهد بحوث صحة الحيوان - فرع الزقازيق
**قسم الفارماكولوجي - كلية الطب البيطري - جامعة الزقازيق

في هذه الدراسة قمنا باختبار إمكانية استخدام البروبوليس أحد العلاجات الطبيعية القليلة التي تمتلك خصائص علاجية قوية ، إلى جانب بعض الأدوية المضادة للبكتريا في علاج مرض الليستيريويزيس الإكلينيكي في الأغنام والماعز الذي تم وصفه و تشخيصه . قد تم فحص 3 قطعان خاصة من الأغنام تحتوي على عدد 485 من الغنم و قطيعين خاصين من الماعز تحتوي على عدد 275 ماعز و التي ظهرت فيها صور اكلينيكية مختلفة لمرض الليستيريويزيس. التشخيص الإكلينيكي تم تأكيده بالفحوصات الهستوباثولوجية و البكتيرية. تم تقسيم الأغنام والماعز المصابة إلي مجموعات، طبقاً للصور الإكلينيكية لمرض الليستيريويزيس ، و ذلك من أجل العلاج الحقلى .

النتائج: في ليستريا الأغنام ، قد أصيب عدد 73 من 485 في الغنم بمعدل عدوى % 15,05 ومعدل إماتة % 10,96. في ليستريا الماعز، أصيب عدد 55 من 275 في الماعز بمعدل عدوى % 20 و دون حدوث حالات إماتة. تبين حدوث الإلتهاب الدماغى بصوره أعلى في الأغنام، في حين كان الإجهاض والتسمم الموى الأكثر حدوثاً في الماعز. وبالفحص الهستوباثولوجي تبين وجود وتجمعات للخلايا وحيدة النواة و خرايج ميكروسكوبية فى أنسجة المخ . بالفحص البكتريولوجى، أسفرت النتائج عن عزل الليستريا مونوسيتوجين بنسبة % 31,09 من الأغنام وبنسبة % 26,98 من الماعز. أظهرت نتائج العلاج الحقلى أفضلية العلاج بالبروبوليس منفرداً أو تابعاً للمضادات الحيوية. فى خفض الشدة الكلية لليستيريويزيس فى الأغنام والماعز المصابة عن تلك التى عولجت بالمضادات الحيوية وحدها (أمبيسلين أو السيفوتاكسيم وحدة) أو السيفوتاكسيم مع خليط الجينتاميسن و الترايميثوبريم و السلفادايثوكسين. وقد وجد أن تأزر البروبوليس مع الأمبيسلين هو الأكثر فاعلية .