

EXPERIMENTAL STUDIES ON CORTICAL BONE XENOGRAFTS: CLINICAL AND RADIOGRAPHICAL ASSESSMENT

El-Keiey, M., Gad Allah, S. and Amer, M.S.

Dept. of Surgery, Anaesthesiology and Radiology
Faculty of Vet Medicine, Cairo Univ.

Received: 26/07/2009

Accepted: 02/08/2009

SUMMARY

An autoclaved cortical bone xenografts of goat cadavers (ACXG) as well as fresh cortical autograft (control FCAG) were successfully used in reconstruction of an experimentally induced segmental femoral defect in canine model. Clinical and radiological assessments were carried out at different periods post-operatively. The obtained results were encouraging and very promising in terms of early return to full limb function at 4-6 weeks post-operatively, cortical union with remodeling were completed at 6 months post-operatively and complete acceptance and incorporation of the graft into the host bone was recorded at 12 months post-operatively. Hence the autoclaved cortical bone xenografts of goat cadavers can offer a worthwhile alternative fo

fresh cortical autografts to veterinary orthopedists.

INTRODUCTION

Bone grafts are extensively used for several orthopaedic applications including treatment of severely comminuted fractures, non union, and replacement of bone loss resulting from tumor or infection, and in cases requiring reconstructive procedures such as fusion or joint replacement (Okumus and Cabnela, 2006).

Various bone graft substitutes including autograft, allograft, xenografts, polymers, ceramics and some metals have been employed to promote bone union (Albee, 1996, and Beaman et al., 2006). Moreover the utilization of these materials as bone grafts may reduce the need for autogenous bone graft, which is available in

limited quantities and is associated with considerable morbidity rate (Stevenson, 1990). An ideal graft substitute should have good bioresorbability (Burchardet, 1987) and osteoconductive capacity (Bob and Peter, 2001). It also should be nontoxic and nonimmunogenic to the organism (Donald and Gretchen, 1997), easy to sterilize (Draenert and Delius, 2007) and not compromise mechanical stability (Gad Allah, 1998).

Although the utilisation of autografts results in significant success in the bone healing process, there are some disadvantages, such as requiring the patient to undergo a second operation and increasing therapeutic costs due to prolonged hospital stay and extended medicare. It is also non convenient in cases of severe bone loss due to extensive destruction or in cases of bone tumors (Scheda et al., 1985). Therefore, the employment of the allograft and xenograft as an alternative to the autograft has become common in orthopaedic surgery (Beaman et al., 2006 and Kumar et al., 2006).

The objective of this experiment was to evaluate the efficacy of autoclaved cortical bone xenografts of goat cadavers in

reconstruction of an experimentally induced bone defects in canine model.

MATERIALS AND METHODS

Donor Animals:

The femurs of apparently healthy native breed goats, weighing about 30-50 kg b.w., of both sexes were cleanly harvested from slaughter house. The surrounding muscles and periosteum were stripped off; the epiphyses were osteoectomized for cleaning of the marrow cavity with a bottle brush and flushing with tap water. The femoral diaphyses were cut into graft segments of 3cm. length using oscillating bone saw. The harvested grafts were defatted with chloroform and ethanol (1:1) for 12 hours then immersed in hydrogen peroxide for 48 hours and flushed with distilled water and lastly it were allowed to dry for 24 hours at room temperature after (Hu, Liu & Lu, 2000).

The bone grafts were individually packed in double wrapped plastic roll, labeled and sterilized by autoclaving at 121°C for 30 minutes (Draenert and Delius 2007). Then it stored at room temperature until used. (Fig. 1)




Figure (1): Cortical bone graft specimens after packing using special plastic roll (A) and sterilization by autoclaving (B).

Recipient Animals:

Twenty adult apparently healthy mongrel dogs of both sexes and weighing 15 to 25kg were used as recipient for cortical

bone xenografts. These dogs were randomly allocated into 4 main groups according to the duration of the experiment and type of implanted bone graft. (Table. 1)

Table (1): Distribution of dogs according to duration of the experiment and type of implanted bone graft

GROUP NO.	DURATION (MONTHS)	NO.OF DOGS	TYPE OF IMPLANTED BONE GRAFT	
			F.C.A.T*(Control)	A.C.X.T**
I	1	5	1	4
II	3	5	1	4
III	6	5	1	4
IV	12	5	1	4
TOTAL		20	4	16

* FCAT: Fresh Cortical Autograft (control group).

** ACXT: Autoclaved Cortical Xenograft.

The pelvic limbs of all operated dogs were radiographed to document normal femoral anatomy and bone size for selection of an appropriate graft by matching host and banked bone graft iographs. A prophylactic antibiotic course of cefotaxim sod.

(Cefotax, Epico, A.R.E) at a dose of 4.5 mg / kg. b.wt. was administered i.v. immediately preoperatively and continued every 8 hours i.m for 5 days post-operatively.

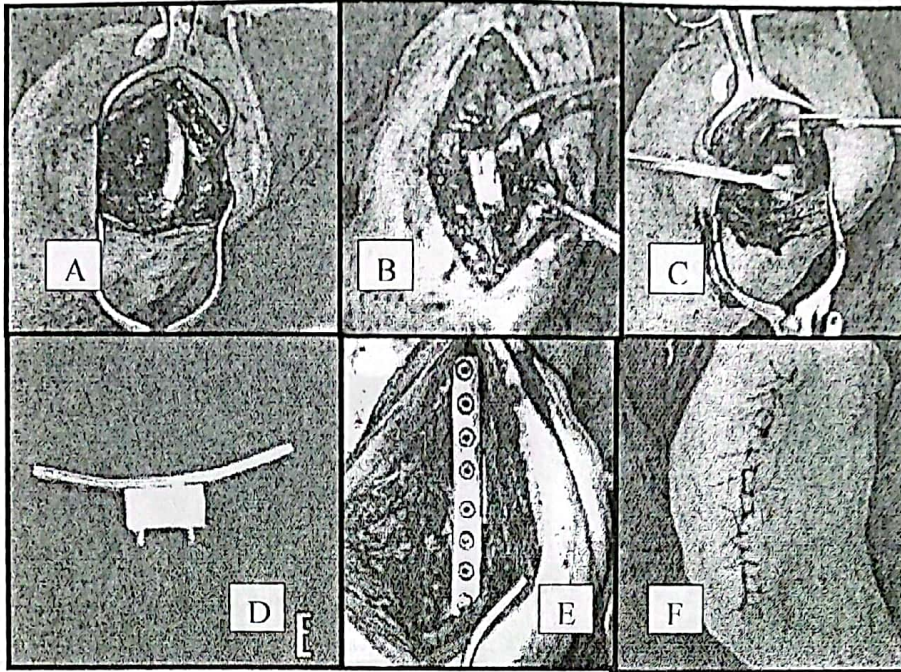
According to the Association for the Study of Internal Fixation (ASIF) a standard orthopaedic bone set and implants were used.

All operated dogs were anaesthetized using the anaesthetic regimen recommended for orthopaedic surgeries in dogs. (Alef & Schmidt-Oechtering, 1995).

The right pelvic limb was prepared for aseptic surgery. A lateral approach to the shaft of the femur was performed (Fig. 2-A). An appropriate graft was selected by matching host and banked grafts radiographs. A mid-diaphyseal segment (3cm) was removed after osteotomy proximally and distally by oscillating bone saw (Fig. 2B). Constant irrigation with sterile saline solution was applied while oscillating to prevent thermal necrosis, the induced defect (Fig. 2 C) was replaced with a cortical bone xenograft segment (3cm) in 4 dogs of each group. The 5th dog received its own ostectomized bone segment after removal of soft tissues and

marrow, to act as a cortical autograft control. The fracture was stabilized and the graft was compressed with an 8-holes 3.5 mm ϕ dynamic compression plate and eight 3.5 mm ϕ cortical bone screws (Synthes, Wayne, Pa) (Fig.2 D & E). The implantation site was flushed several times with sterile saline solution. The surgical wound was closed as usual (Fig. 2F). All operated dogs were confined to individual cages along the duration of the experiment (1-12 months). They were subjected to daily clinical examination, including weight bearing capacity, evidence of infection, full limb function and local reaction and regional lymph node enlargement.

Sequential radiographs of the operated femur of living animals were taken immediately postoperatively, once every two weeks for the next 3 months and then once per month until the end of the study. Radiographs were evaluated for alignment of the graft with the host bone, metal implant stability, the degree of contact at the osteotomy sites, signs of graft incorporation at the proximal and distal host-graft interfaces, callus formation and radiodensity of the graft. After euthanasia the harvested femurs were underwent to contact radiography before and after removal of the plate to confirm the same radiographic patterns recorded during the life of animals.



(Figure 2): Stages of cortical bone xenografting


- A. Exposure of femoral shaft
- B. Removal of a mid-diaphyseal segment 3 cm length
- C. The induced defect
- D. Fixation of the graft into the plate (DCP) by using two cortical screws.
- E. The plate-graft combination was fixed into the recipient femur to bridge the induced defect using 6 cortical screws (3 proximal and 3 distal)
- F. Closure of the S/C and the skin as usual.

RESULTS

Clinical evaluations:

In case of fresh cortical autograft (control group), all operated dogs were partially weight bearing on the operated limb

by 3-5 days post-operatively and they showed full weight bearing at the 4th week post-operatively. The gait was varied from occasional lameness to full limb function by the end of 12 weeks post-operatively. (Fig. 3 A, b &c)



(Figure 3): Clinical evaluation of weight bearing capacity and gait of a dog received a Fresh Cortical Bone Autograft (FCAG) at different observation periods. Note that the dog started to land at 3-5 days post-operatively(A), walking and standing (B & C) i.e. full limb function at 4 weeks pt-operatively.

No clinical evidence of infection. Rectal temperature was within normal limit during the observation periods. The popliteal node was slightly enlarged during the first week post-operatively. There was a moderate degree of seromal reaction in two dogs and severe reaction in another one. These reactions were subsided spontaneously within 1-2 weeks post-operatively.

In case of autoclaved cortical bone xenografts. Out of 16 operated dogs, twelve dogs were partially weight bearing on the operated limb at one week post-operatively and they showed full weight bearing at 6 weeks post-operatively. The signs of lameness were almost disappeared by 16-24 weeks post-operatively with full limb function (Fig. 4A, B & C).




Fig. (4): Clinical evaluation of weight bearing capacity and gait of a dog received Autoclaved Cortical Bone Xenograft (ACXG) at different observation periods. Note that the dog started to land at one week post-operatively (A), walking and standing (B & C) i.e. full limb function at 6 weeks post-operatively.

The rectal temperature was within normal limit with slight elevation ($0.5-1^{\circ}\text{C}$) in 3 dogs which returned to normal within 3 days post-operatively. The popliteal lymph nodes were enlarged and palpable during the first two weeks post-operatively and returned back to normal by the end of the first month.

Moderate degree of seroma reaction was observed in all operated dogs 2-3 days post-operatively which spontaneously subsided by the end of the first week except in two dogs. The latter's showed subcutaneous draining sinuses one week post-operatively. These

dogs were successfully treated by free drainage and dressing in conjunction with systemic antibiotic course of cefotaxim 4.5 mg/kg twice daily.

II. Radiographic Evaluations

Sequential Radiographic Assessment

The results of sequential radiography of fresh cortical autograft control and autoclaved cortical xenografts at different observation periods were illustrated in tables 2 & 3 while figures (5) and (6) were showing the radiographic picture of graft incorporation.

Table (2): Follow-up sequential radiography of 4 successful cases of fresh cortical bone autografts (FCAG) (control group)

Observation Periods (weeks)	Alignment	Periosteal reactivity		Host-Graft interfaces		Graft visibility
		Host	Graft	proximal	Distal	
Immediate P.O	Very Good	-	-	A	A	Visible proximally and distally
2 weeks P.O	Very Good	+	-	A	A	Visible proximally and distally
4 weeks P.O	Very Good	++	+/-	B	A	Invisible proximally (25%) and visible distally
6 weeks P.O	Very Good	+++	+	C	B	Invisible proximally (50%) and invisible distally (25%)
8 weeks P.O	Good	++	++	C	C	Invisible proximally (75%) and Invisible distally (50%)
12 weeks P.O	Good	+/-	+++	D	C	Invisible proximally (100%) and invisible distally (50%)
16 weeks P.O	Good	-	++	E	D	Invisible proximally (100%) and invisible distally (75%)
20 weeks P.O	Good	+	+	E	E	Invisible proximally (100%) and invisible distally (100%)
24 weeks P.O	Good	+/-	+/-	E	E	Invisible proximally and distally
30 weeks P.O	Very Good	-	-	E	E	Invisible proximally and distally except at mid-graft
36 weeks P.O	Very Good	-	-	E	E	The graft nearly had the same radiodensity of the host bone
48 weeks P.O	Very Good	-	-	E	E	The radiodensity of the graft was homogenous to the radiodensity of the host bone.

• **Good:** slight disparity between the graft and host bone.

Very good: the graft nearly had the same size of the host bone.

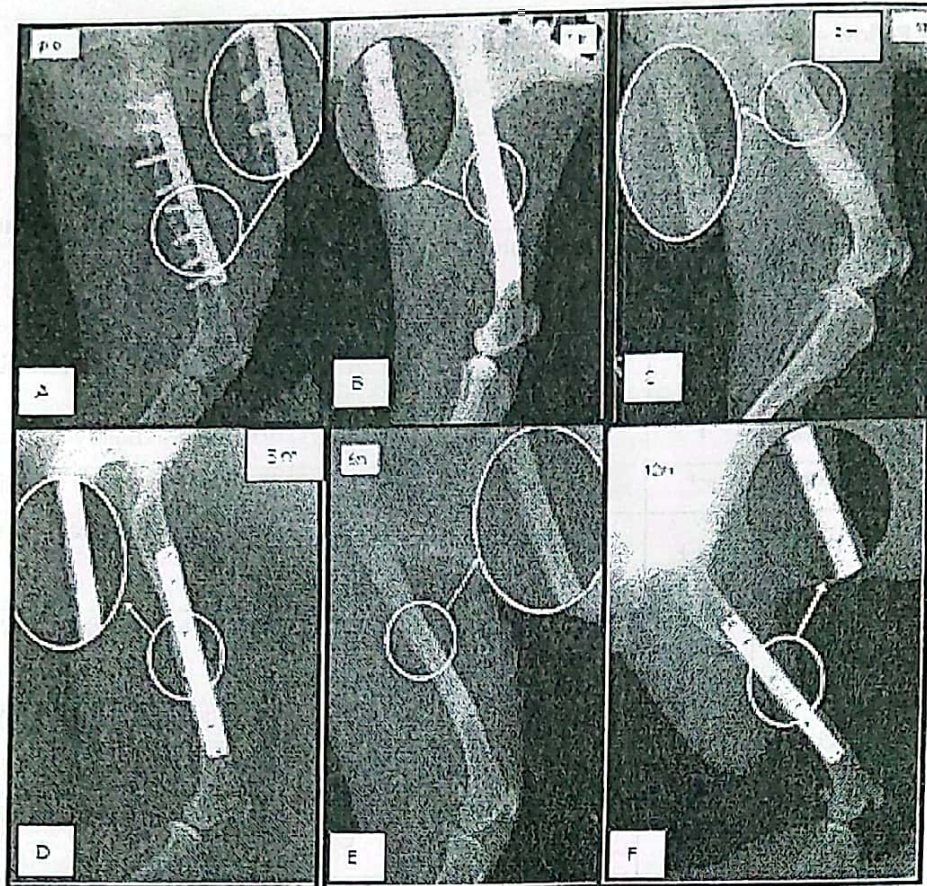
• (-) : No periosteal reactivity, (±): Negligible, (+): slight, (++) : moderate, (+++) : excessive.

• (A) : visible 100%, (B): partial filling 25%, (C): partial filling 50%, (D): partial filling 75%, (E): complete union & remodeling.

Table (3): Follow -up sequential radiography of 12 successful cases of autoclaved cortical bone xenografts (ACXG)

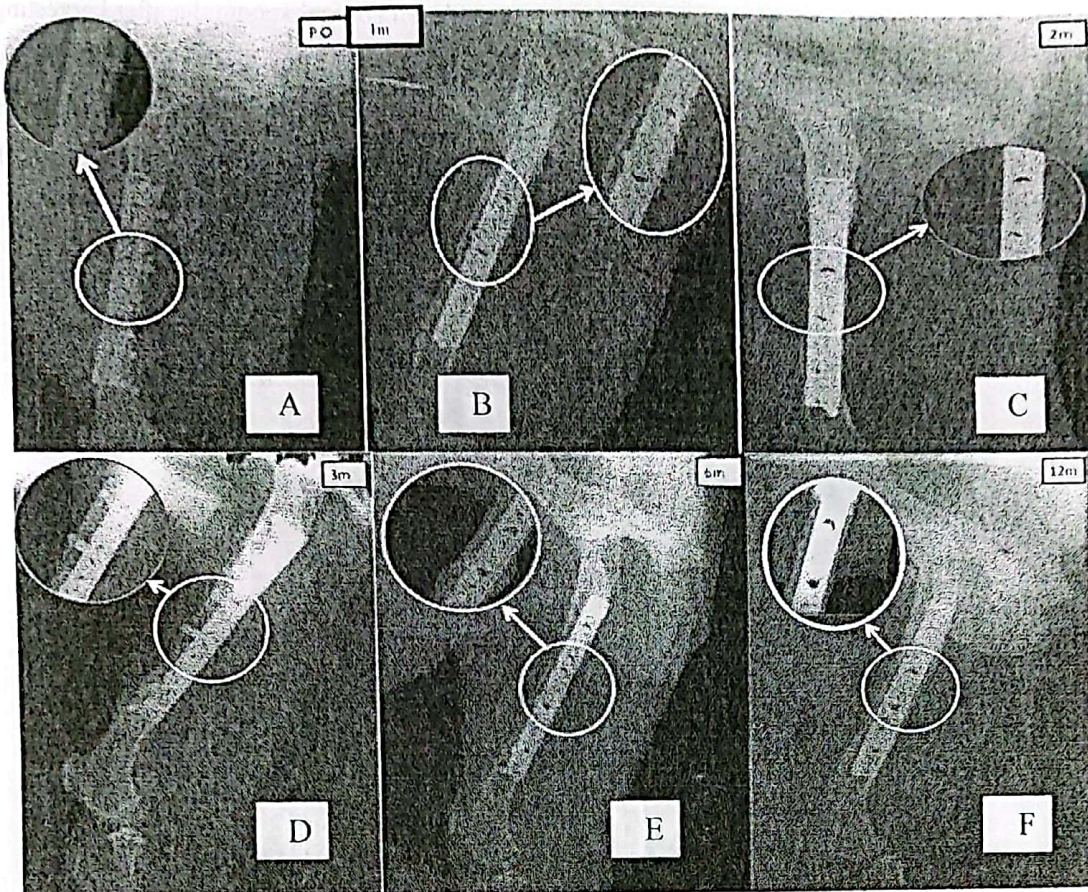
Observation period (weeks)	Alignment	Periosteal reactivity		Host-graft interfaces		Graft visibility
		Host	Graft	proximal	Distal	
Immediate P.O	Good	-	-	A	A	Visible proximally and distally
2weeksP.O	Good	+	-	A	A	Visible proximally and distally
4weeksP.O	Good	++	-	A	A	Visible proximally and distally
6weeksP.O	Good	+++	±	B	A	Invisible proximally (25%) and visible distally
8weeksP.O	Good	+++	+	C	B	Invisible proximally (50%) and distally (25%)
12weeksP.O	Good	++	++	C	B	Invisible proximally (50%) and distally (25%)
16weeksP.O	Good	+	+++	D	C	Invisible proximally (75%) & distally (50%)
20weeksP.O	Good	+/-	+++	E	D	Invisible proximally (100%) & distally (75%)
24weeksP.O	Good	-	++	E	D	Invisible proximally (100%) & distally (75%)
30weeksP.O	Good	-	+	E	E	Invisible proximally (100%) & distally (100%)
36weeksP.O	Very Good	-	±	E	E	Invisible proximally & distally except at mid-graft
48weeksP.O	Very Good	-	-	E	E	The graft density was nearly had the same radiodensity of the host bone

- **Good:** slight disparity between the graft and host bone.
- **Very good:** the graft nearly had the same size of the host bone.
- (-): No periosteal reactivity, (±): Negligible, (+): slight, (++) : moderate, (+++) : excessive.
- (A) visible 100%, (B): partial filling 25%, (C): partial filling 50%, (D): partial filling 75%, (E): complete union & remodeling.



(Figure 5): Sequential Medio-lateral radiographs of fresh cortical autograft (FCAT).

- (A) Immediate post-operative showing adequate alignment and metal-implant stability, the degree of contact of osteotomy sites at the proximal and distal host graft-interfaces was about 70-100%
- (B) At one month P.O showing rounding off the edges of the host bone segment accompanied with the start of periosteal reactivity over these areas.
- (C) At two months P.O the process of rounding off occurred in the graft segment with periosteal new bone deposition on the graft surface
- (D) At three months P.O. showing the proximal fracture line was completely disappeared, while the distal one was almost disappeared
- (E) At 6 months P.O. showing cortical union at the proximal and distal host-graft interfaces along with excellent alignment had occurred
- (F) At twelve months, the graft density was homogenous with the host bone density



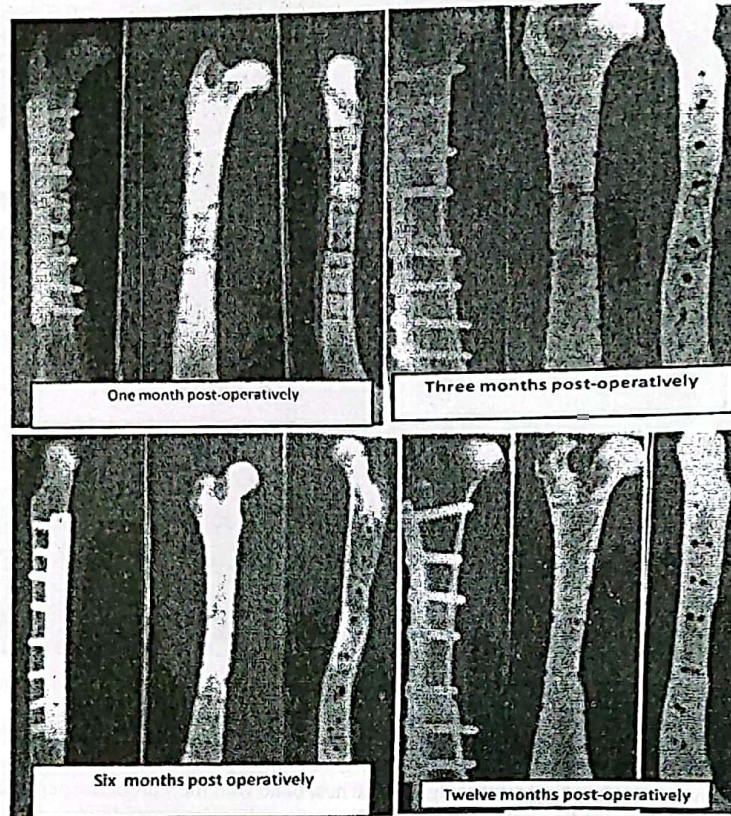
(Figure 6): Sequential Medio-lateral radiographs of full thickness Autoclaved Cortical Bone Xenografts: (ACXG)

- (A) Immediate post-operative, showing the proper alignment at the host-graft interfaces and the stability of the fixation device. The degree of contact of osteotomy site at the host-graft interface was 50-70%.
- (B) At 1 months P.O., showing the rounding off the edges of the host bone with the start of the periosteal reactivity.
- (C) At 2 months P.O., showing rounding off the edges of the graft and initiation of liping callus at the host graft interfaces starting from the proximal one.
- (D) At 3 months P.O., showing disappearance of the proximal host-graft interface and the radiodensity of the graft is less than the host bone.
- (E) At 6 months P.O., showing disappearance of both host-graft interfaces.
- (F) At 12 months P.O., showing the homogeneity in the radiodensity along the bone.

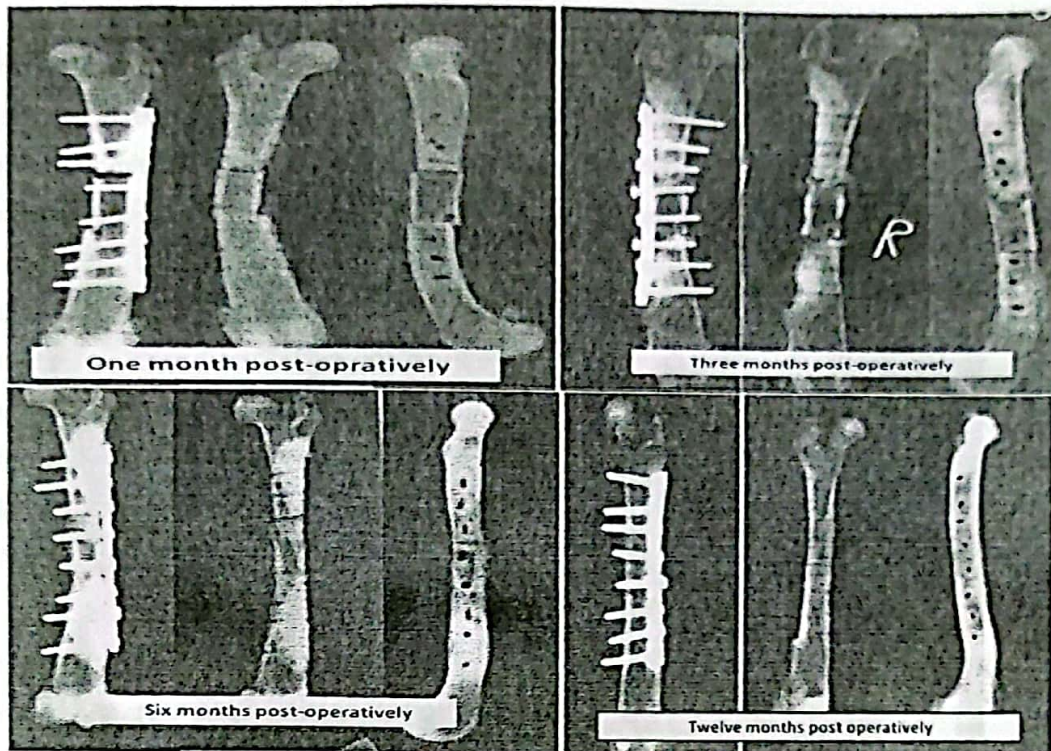
Contact radiographic Assessment

The results of contact radiography of fresh cortical autografts (control group) and

autoclaved cortical xenografts after harvesting of the operated femur at one month, 2 months, 6 months and 12 months post-operative times were illustrated in figures (7) and (8).



- (Figure 7): Contact radiography of Fresh Cortical Autograft (FCAT) control after harvesting:*
- * At one month post operatively, showing slight periosteal and endosteal bridging callus particularly at the proximal host-graft interface. The proximal gap was filled with radiodense material (50%) while the distal one was visible and filled with (25%). the cranial and caudal cortices of the graft were radiodense.
 - * At three months post-operatively, showing cortical union along with remodeling at the proximal host-graft interface. The distal gap was nearly disappeared.
 - * At six months post-operatively, showing cortical union at the proximal and distal host-graft interfaces. The cranial and caudal cortices of the graft were more radiodense except at the proximal host-graft interface.
 - * At twelve months post-operatively, showing complete incorporation of the graft into the host bone. The radiodensity of the graft was nearly similar to the radiodensity of the host bone.

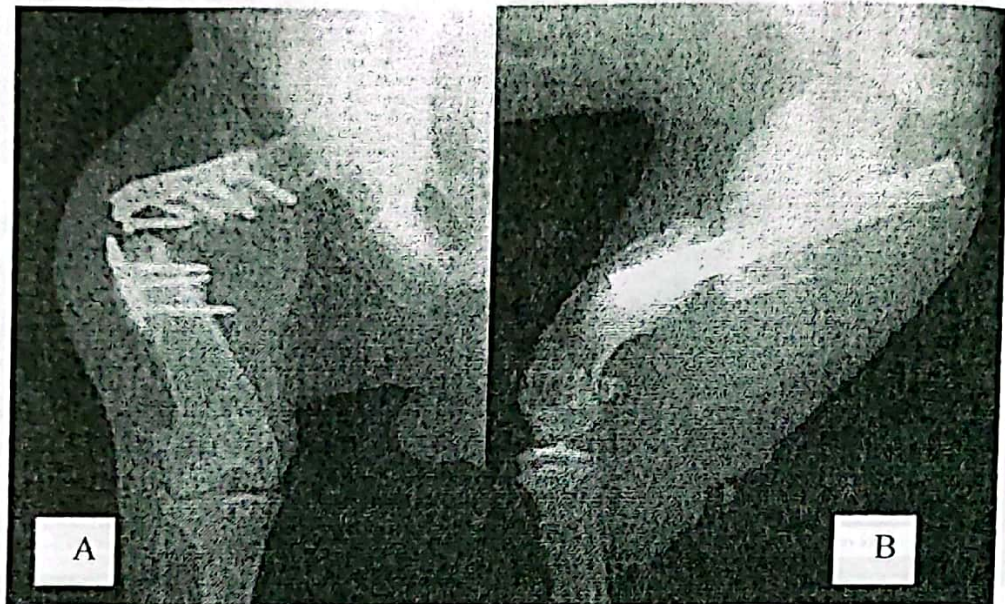

(Figure 8): Contact radiography of autoclaved cortical xenograft (ACXG) after harvesting:

- * At one month post-operatively, showing periosteal bridging callus crossing the fracture gap at the proximal and distal host-graft interfaces. The graft was more radiodense throughout, the proximal and distal gaps were visible.
- * At three months post operatively, showing the periosteal and endosteal callus bridging the fracture gap and creeping over the graft (lipping) proximally and distally. The graft appears more radiodense at the mid region. The proximal gap was filled with radiodense material (75%) while the distal one still visible (50%).
- * At six months post-operatively, showing cortical union proximally and distally with starting of medullary remodeling proximally. The cranial and caudal cortex of the graft were radiodense particularly at the mid graft.
- * At twelve months post-operatively, showing complete acceptance and incorporation of the graft into the host bone. The radiodensity of the graft was nearly similar to the host bone. The caudal cortex was somewhat radiopaque.

Complications of xenografting procedure were recorded in 4 dogs. They included implant failure as a result of broken plate and

screws in two cases (one, G I and one, G II) (Fig. 9.A) and fracture of xenografts in another two dogs (G II) (Fig. 9-B).



(Figure 9): The recorded complications of autoclaved cortical bone xenografts
A. A/P radiograph showing implant failure as result of broken plate and loose cortical screws
B. L.M radiograph showing sagittal fracture of the graft, instable fixation and huge callus at the proximal fragment of the host bone.

DISCUSSION

Cortical bone grafts which were used to promote osteogenesis, restore the contour, provide union between two fragments of bone and provide a frame work which has structural integrity (Bob and Peter, 2001). Although autogenous bone grafts performs those functions satisfactorily, problems of limited supply, prolonged operation time and donor site morbidity has prompted to research into another type of bone grafts (Dehaghani and Baizaei, 2001).

In the present study an autoclaved cortical bone xenografts of goat cadavers were successfully used in repair of an experimentally induced femoral defect in canine model. The ingredients for this success included the existence of a feasible simplified bone bank and rigid fixation of the implanted xenograft into the recipient bed using standard ASIF plating technique.

Most of tissue banks use frozen bone which is obtained under aseptic condition from carefully screened cadaver donors (Stevenson, 1990). In the present study the

advantages of using the method of bone harvesting, sterilization and storage are numerous as donor screening for infectious disease is minimal because the lethal effect of steam vapor on the infective agent; the ability to collect the bone specimen without aseptic technique shortens and simplifies the bone banking procedure. The findings are more or less similar to those reported by Draenert and Dellius (2007) who recommended steam vapor sterilization for bone grafts particularly in third world countries.

The absolute stability achieved in plate fixation is a requirement for optimal incorporation of the grafts by the host bone (Sinibaldi, 1989). The best quality of the stored bone is an essential factor for cortical xenograft implantation, as the dehydrated and brittle bone will not allow the preparations necessary for plate application and screw fixations. In this study the selected xenograft was rehydrated in sterile saline solution prior to implantation to improve the mechanical properties of the graft as recommended by (Gadallah, 1998).

The results of clinical assessment of 16 dogs received an autoclaved cortical bone xenografts and 4 dogs received its own cortical autograft (control group) were encouraging. The majority of dogs (80%) did extremely well and they were bearing weight on the operated limb within 2-4 weeks post-operatively. While full limb function was

obtained by the end of 12 weeks P.O. There was no evidence of infection or immunologic reaction as assessed by visually or palpably monitoring the degree of seroma, local changes, popliteal lymph node reaction and presence or absence of wound drainage. These observations were correlated well with those reported by Dehaghani and Baizae (2001), Kumar et al., (2006) and Rouvillain et al., (2006).

Seroma and popliteal lymph node enlargement were the most marked reactions observed in all operated dogs at 3-5 days post-operatively. These reactions disappeared spontaneously within two weeks with out interference in all dogs received fresh cortical autografts. While in those received autoclaved cortical xenografts, these reactions were also disappeared spontaneously by the end of the first month. Similar findings were reported by Dell et al., (1984) and Burchardet (1987) for fresh cortical autografts. They attributed these reactions to surgical trauma and non specific foreign body response. However, none of the available literature studied autoclaved cortical xenografts.

Radiography is a basic method for evaluating fracture healing in both clinical and experimental models. Radiographs obtained at regular intervals during the healing process provide a convenient technique for sequential assessment of the bone healing defect, such parameters as bone

formation, persistence of fracture gap and remodeling can be evaluated in living animals at any number of predesignated time periods (Lane and Harvinder, 1987 and Sinibaldi, 1989).

The process of incorporation and replacement of non viable cortical bone grafts (Creeping substitution) was divided into 3 radiographic phases. The initial phase persisted from 2 to 4 weeks and involved a passive relationship between the host and graft. Therefore the graft appeared more radiopaque with out any significant changes in its morphology. The second phase was cortical union; the graft was merely united to the host bone by an organized network of bone trabeculae (bridging callus). The final phase lasted from many years and involved continuous replacement of the graft with continuous decrease in its size (Bowerman, and Hughes, 1975; Dell et al., 1984).

In the present study, sequential and contact radiography of the operated femurs showed that, the existence of bone resorption at 2 to 3 week earlier in the host bone segment than the graft (Rounding off). This process was noted in the cortical autografts 3 weeks post-operatively and in the autoclaved cortical xenografts at 4-6 weeks post-operatively. Presumably, this was due to active circulatory supply in the host bone cortex which is created as result of osteotomy.

Similar findings were reported by Gebhart and Lane (1991).

Concerning with the host-graft interfaces, the proximal interface was completely bridged by periosteal new bone at the 12th week in fresh cortical autograft and at 20 weeks post-operatively in autoclaved cortical bone xenografts, the values at the distal interface for the respective grafts were 24 and 30 weeks. Schena et al., (1985) and Gadallah, (1998) have attributed this fact to the presence of nutrient artery dorsal to the proximal interface. Meanwhile the normal anatomy of the dog's femur which curved craniomedially at its distal third may cause instability at the distal host bone segment.

Regarding the periosteal remodeling, the periosteal callus started to be remodeled at 8 weeks post-operatively and reached completion at the 16th week for the fresh cortical autograft. While it begun to be remodeled at 12 weeks and completed at 24 weeks in xenografted dogs. Such findings were mentioned by Johnson et al., (1985) and Andersen et al., (1995).

In the present study, cortical unions had occurred once periosteal bridging was completed, the approximate time of cortical union at the proximal interface of the fresh cortical autografts was 12 weeks as compared to 20 weeks in autoclaved cortical xenografts. While at the distal one, these values were 20 weeks in control and 30 weeks in autoclaved

cortical xenografts. The findings of control group were similar to those reported by Donald and Gretchen (1997) and Gadallah (1998).

Regarding the graft radiodensity, the present study showed that, the fresh cortical autograft was difficult to be identified at 48 weeks post-operatively. The radio density of the graft was homogenous with the radiodensity of the host, however, the autoclaved cortical xenografts were slightly more radiodense particularly at its middle third. This is in agreement with those reported by Johnson et al., (1985) and Sinibaldi, (1989) who mentioned that at one year P.O, up to 40% autogenous cortical bone graft may not be remodeled.

Regarding the complications encountered with autoclaved cortical bone xenografting procedures, implant failure as a result of broken plate and loose screws were recorded in two cases received autoclaved cortical bone xenografts. This condition may be attributed to hyperactivity of these dogs and bad quality implants (plates and screws). Similar findings were reported by Johnson et al., (1985). Longitudinal fractures of xenografts were observed in two cases. This condition may attribute to instability at implantation site as well as weakening of the mechanical strength of the xenograft particularly when the resorptive phase has outstripped the appositional phase. These findings are in

agreement with these reported by Gadallah (1998).

In conclusion, the results of the present study revealed that the incorporation of autoclaved cortical bone xenografts of goat cadavers into femoral defect repair in canine model was successful as determined by the achievement of full limb function, fracture healing and graft remodeling. These results are promising for the clinical application of such graft procedures and may pave a way in using this type in extensive bone injuries and defects/ bone resections due to neoplastic disorders. Further studies are required to answer the questions concerning the immunogenicity, biomechanical properties and bone remodeling rates.

REFERENCES

- Albee F. H. (1996): Bone graft Surgery. Clinical Orthopedics and Related Research, 324:5-12.
- Andersen, JR., Detlie, T and Griffiths, J.J. (1995): The radiology of bone allografts. Radiologic Clinics of North America, 33: 391-400.
- Beaman, F. D.; Bancrofts, LW; Peterson, JJ and Kransdorf, M. F. (2006): Bone graft materials and synthetic substitutes. Radiol. Clin. North Am. 44(3): 451-461.
- Bob, P.; and Peter, J.F (2001): Physiological aspects of xenotransplantation. Transplantation Rev., 15 (4): 200-209.
- Bowerman, JW, and Hughes, JL. (1975): Radiology of bone grafts. Radiol. Clin. North. Am. 13:67.

- Burchardet, H. (1987): Biology of bone transplantation. *Orthop. Clin. North Am.*, 18 (2): 187-196.
- Dehaghani, SN; Baizaei, FE. (2001): Using xenografting bovine bone pin for fracture repair in dogs. 27th world Small Animal. Vet. Asso, Congress Proceeding. Vancouver, British Columbia Canada.
- Dell, P.C., Burchardet, H., and Glewoczski, FP; (1984): A roentgenographic, mechanical and histological evaluation of vascularized and non vascularized segmental fibular canine autografts. *J. Bone Joint Surg.*, 67: 105-112.
- Donald, L P and Gretchen, L.F (1997): Bone grafting: In Small Animal orthopaedics and fracture repair, (3rd edition). W.B. Saunders Co., Philadelphia, Pennsylvania PP 147-149.
- Draenert, GE., and Delius, M. (2007): The mechanically stable steam sterilization of bone grafts. *Biomaterials* 28 (8): 1531-1538.
- Gadallah, SM (1998): Studies on entire segment cortical bone allografts in dogs. PhD. Vet. Thesis Cairo University. Giza.
- Gebhart, M., and Lane, J., (1991): A Radiological and biomechanical study of demineralized bone matrix implanted into a bone defect of rat femur with or without bone marrow. *Acta. Orthop. Bedg.* 57: 130-143.
- Hofmann, C.; Schadel -Hopfner, M.; Berns, T.; Sitter, H.; and Gotzen, L. (2003): Influence of processing and sterilization on the mechanical properties of pins made from bovine cortical bone *Unfallchirurg*, 106 (6): 478-482.
- Johnson, Al; Shokry, MM and Stein, LE (1985): Preliminary study of Eo sterilization of full thickness cortical allograft used in segmental femoral fracture repair. *Am. F. Vet. Res.* 46 (5): 1050-1056.
- Kumar, P.; Shrestha, D.; and Bajracharya, S. (2006): Replacement of an extruded segment of radius after autoclaving and sterilizing with gentamycin, *J. Hand Surg.*, 31-8 (6): 616-618.
- Lane, JM., and Harvinder, SS, (1987): Current approaches to experimental bone grafting, 18 (92): 213-225.
- Okumus, DA., and Cabnela, ME. (2006): Impaction bone grafting for revision hip arthroplasty. Biology and clinical application. *J. Am. Acad. Orthop. Surg.*, 14: (11): 620-628.
- Rovillain, JL; Navarre, T., Nosedo, O., and Garron, E; (2006): Traumatic femoral bone defect reconstruction with an autoclaved autologous femoral segment: A 10 years follow-up. *Acta. Orthop. Belg.* 72 (2): 229-233.
- Schena, C.J.: Mihen, RW, and Hoefle, WD (1985): Segmental freeze - dried fresh cortical allografts in the canine femus. II: A sequential histologic comparison over a one year time interval. *Am. Anim. Hosp. Assco.* 21: 193-204.
- Schmidt-Ochtering and Alef. (1995): *Neue Aspekte der Veterin. Anästhesie, und Intensivtherapie*, Blackwell Wissenschafts-Verlag. Berlin.
- Sinibaldi K R. (1989): Evaluation of cortical allografts in 25 dogs. *JAVMA*, 194 (11: 15 70-1577).
- Stevenson, S., (1990): Bone grafting in Bojarb, J. (3d): *Current techniques in small animal surgery*, Lea & Febiger, Philadelphia, USA. PP 836-843.
- Yun-Yu. Hu; Wei Lieu; Yu - Pu lu; (2000): Recombined xenograft of cancellous bone graft and bone morphogenic protein (BMP) *The Iowa orthopaedic Journal*, Vol., 11: 54-58.

دراسة تجريبية على زرع طعوم عظمية قشرية غير متجانسة متابعة إكلينيكية و راديولوجية

محمد طه القيعى - شعبان محمد جاد الله - محمد سعيد مصطفى
قسم الجراحة و التخدير و الأشعة - كلية الطب البيطرى، جامعة القاهرة

استهدفت هذه الدراسة معرفة مدى ملائمة العظم القشرى الغير متجانس للماعز بعد معاملته و تعقيمه فى الأوتوكلاف بإندماجه بالنسيج العظمى للكلاب المستقبلية لهذه العظام و ذلك من خلال المتابعة الإكلينيكية و الشعاعية على مدار اثنى عشر شهراً.
تم تقسيم هذه الدراسة إلى مرحلتين :

المرحلة الأولى : إعداد بنك للعظام من عظام الفخذ للماعز

تم تجميع عظام الفخذ من الماعز بدون تعقيم بعد ذبحها فى المجزر حيث جردت هذه العظام من كافة الأنسجة و العضلات و تم تقطيع ساق هذه العظام إلى قطع متساوية كل قطعة طولها 3سم. بعد تجفيف و تغليف هذه العظام تم تعقيمها فى الأوتوكلاف عند درجة 121 لمدة نصف ساعة بعد ذلك تم حفظها عند درجة حرارة الغرفة.

المرحلة الثانية : استخدام العظم القشرى الغير متجانس للماعز و المحفوظ فى بنك العظام فى ترقيع العيوب المستحدثة لعظمة الفخذ فى الكلاب

شملت هذه الدراسة عشرون كلباً من كلاب التجارب تم استخدامها كمستقبل بعد إجراء إزالة جراحية للأجزاء المتساوية من الثلث الأوسط لساق عظمة الفخذ بطول 3 سم للقائمة الخلفية اليمنى تم ترقيع العيوب المتحدثة باستخدام عظم الماعز المعقم فى اوتوكلاف و المحفوظ فى بنك العظام فى عدد 16 كلب من كلاب التجارب ، حيث استخدمت الشرائح المعدنية و المسامير الحلزونية كوسيلة للتثبيت استخدمت مجموعة للتحكم باستخدام عظام مزروعة من نفس الكلب و عددها 4 كلاب.

اثبتت نتائج الفحص الإكلينيكي و الراديولوجى و التى أجريت على مدار اثنى عشر شهراً أن العظام الغير متجانسة و المعقمة بالاتوكلاف (عظام الماعز) يمكن ان تندمج بالنسيج العظمى للحيوانات المستقبلية (الكلاب) دون ادنى مضاعفات بالإضافة إلى كفاءة استخدام الأوتوكلاف كوسيلة فعالة لإنشاء بنك العظام بأقل التكاليف و أبسط الوسائل.