

Radiographic Assessment of Normal Coxofemoral Joints of Labrador Retrievers

Menna A. Nahla^{1*}, Ayman A. Mostafa¹, Khaled M. Ali¹

1. Department of Surgery, Faculty of Veterinary Medicine, Cairo University, Giza, Egypt

* Correspondence author; Menna A. Nahla, e-mail: mnnatya@gmail.com; Tel. +201094726106

1. Abstract

Objectives: To quantify lateral and dorsal acetabular femoral head (AFH) coverage in normal coxofemoral joint of Labrador retrievers and to evaluate the degree of steepness of the cranial acetabular edge (acetabular slope ‘AS’ angle) and inclination angle (IA) in normal hips.

Methods: The investigated group was categorized as normal coxofemoral joints according to the morphometric criteria established by the FCI system. Centre-edge (CE) angle, Norberg angle (NA), indices of dorsal AFH coverage width and area, acetabular index angle, and inclination angle were determined. Mean (\pm SD) values related to all parameters were calculated. A spearman correlation coefficient determined the relationship between selected variables.

Results: Significant correlations were identified between NA and CE-angle ($r_s = 0.58$, $P < 0.0001$), and between the width and area of dorsal AFH coverage ($r_s = 0.86$, $P < 0.0001$). Weak correlations were determined between the radiographic techniques used to assess lateral versus dorsal AFH coverage. A weak negative correlation ($r_s = -0.48$, $P < 0.0001$) was determined between acetabular slope (AS) angle and CE angle. Inclination angle did not correlate with any of other radiographic measurements reported in our study.

Conclusions: The present study concluded that, radiographic evaluation of dorsal AFH coverage width and area index, CE-angle and IA (Inclination angle) during selective breeding reduce the prevalence of CHD among offspring. Coxofemoral joints with dorsal AFH coverage width index $\geq 55\%$, area index $\geq 59\%$, CE-angle $\geq 27^\circ$ and IA ranges between 130° - 132° are expected to be perfectly normal.

Key words: *hip dysplasia, radiography, acetabular, femoral head, coverage, Labradors.*

2. Introduction

Canine hip dysplasia (CHD) is a common orthopedic problem represents 30% of the overall orthopedic diseases [1]. It is a developmental disorder that affects the hip joint in which associated instability and incongruity of the joint lead finally to osteoarthritis [2, 3]. It affects rapidly growing large breed dogs [4], with high prevalence seen among German Shepherds, Labrador Retrievers and Boxers [5, 6]. Extended ventrodorsal (VD) pelvic radiograph remains the most commonly

used technique for evaluation of the canine hip joint according to the FCI (Federation Cynologique Internationale), OFA (Orthopedic Foundation for Animals), and BVA/KC (British Veterinary Association and the Kennel Club) [7].

Various radiographic measurements have been used for evaluation of canine coxofemoral joint [8]. Norberg Angle (NA) is commonly used to evaluate CHD via assessing the degree of acetabular coverage of femoral head (FH) [9, 10]. NA does not accurately represent hip joint conformation or laxity and thus has weaknesses as a

selection criterion [11]. In human literatures, Centre-edge (CE) angle and acetabular index/slope (AS) angle were previously established to determine the degree of acetabular FH coverage (CE) and calculate the steepness of acetabular roof (AS) of each joint separately [12]. Femoral overlap is also known as % coverage of the femoral head by the acetabulum [7]. The Inclination angle of the femur is important biomechanically in the transfer of forces from the femur to the acetabulum [13]. There are two methods to measure it (method A and method B) [14, 15]. Values of the inclination angle vary depending on the method that used to measure it [13]. The main aim of the present study was to evaluate the overall coverage (lateral and dorsal) acetabular coverage of FH in normal coxofemoral joints of Labrador retrievers. The 2nd aim is to evaluate the steepness of cranial acetabular edge and the angle of inclination in the normal hip joints. Our long-term goal is to achieve a selective breeding program using parents with radiographically healthy coxofemoral joints to reduce the incidence of CHD among offspring.

3. Materials and Methods

3.1. Population

The retrospective study protocol was approved by the Scientific Committee of the Department of Surgery and Radiology at the Faculty of Veterinary Medicine, Cairo University before investigation. Adult Labrador Retrievers showing normal hip joints were investigated in the present study using their medical records and extended VD pelvic radiographs. The study included radiographs which agree with terms of quality and positioning (with parallel femurs and no pelvic tilting) [16, 17]. All approved radiographs were made sure that there are all normal according to the morphometric criteria previously established by the FCI scoring protocol of CHD by a qualified radiologist (AM) [7,

18, 19]. Accordingly, hip joint was considered normal (grade A) if coxofemoral joint perfectly congruent, show narrow space sharply margined, perfectly parallel articular margins and a $NA \geq 105^\circ$.

3.2. Radiographic measurements

Firstly, a best fit circle was drawn outlining the femoral head, defining its center, and calculating its area, and then six radiographic parameters were measured for each hip joint. The Centre-edge (CE) angle and Norberg angle (NA) measures quantify the degree of lateral acetabular FH coverage in the hip joint. The NA was measured in accordance with other veterinary literatures [19, 20]. The CE angle was measured modified from human techniques [21, 22], formed by two straight lines originating from the center of the FH, a line tangential to lateral acetabular rim, and a second line parallel to the longitudinal axis of the body of the corresponding ilium (iliac axis, [10]) (Figure 1A).

Indices of dorsal acetabular FH coverage width and area to determine the extent of dorsal acetabular FH coverage in hip joint, were measured as follow: the index of dorsal acetabular coverage area was calculated by dividing the area of FH covered by dorsal acetabulum and bounded laterally by dorsal acetabular edge by the overall FH area (Figure 2A); and the index of dorsal acetabular FH coverage width was measured by drawing FH diameter perpendicular to and bisecting the dorsal acetabular edge, then calculated by dividing the width of dorsal acetabular coverage by FH diameter (Figure 2B). The acetabular index/slope (AS) angle quantify steepness of cranial acetabular edge (sourcil slope), was measured in modified way from human technique [12, 22]. It was formed between a line connecting the lateral and medial extents of the sclerotic cranial acetabular edge (acetabular sourcil) and a horizontal line perpendicular to the corresponding

iliac axis (Figure 1B). The inclination angle was measured to evaluate the proximodistal alignment of the femoral head and neck relative to the corresponding femoral axis. It was measured as previously described by veterinary literatures [9, 10, 13, 14, 15]. All radiographic measurements on digitized radiographs were performed by the same investigator (MN) using medical and radiologic image processing software (ImageJ 1.41/Java 1.6.0-21) with a magnification of 200 [9, 10].

3.3. Statistical analysis:

Data analysis was performed using commercially available statistical software (Graph-Pad Prism version 8.00, La Jolla, California, United States). Data were tested for normality using Kolmogorov-Smirnov test. A Spearman rank correlation coefficient (r_s) was calculated to determine relationship between selected variables. Mean (\pm SD) values and 95% CIs of all parameters were calculated.

4. Results

4.1. Population

A total of 72 purebred Labrador retrievers (111 coxofemoral joints) with radiographically normal coxofemoral joints were investigated. There were 33 luxated coxofemoral joints excluded from the study.

4.2. Radiographic measurements

Mean (\pm SD) values and 95% CIs for all reported radiographic measurements are summarized in table 1. A moderate positive correlation ($r_s = 0.58$, $P < 0.0001$) was identified between Norberg and CE angles (Fig 3A). Furthermore, there was a strong positive correlation ($r_s = 0.86$, $P < 0.0001$) between the two indices (width and area) that quantified the degree of dorsal AFH coverage (Fig 3B). There is a weak correlation were determined between the

radiographic techniques used to assess lateral versus dorsal AFH coverage. A weak negative correlation ($r_s = -0.48$, $P < 0.0001$) was determined between CE angle and acetabular slope (AS) angle (Fig 3C). No correlation between the inclination angle and any of the radiographic measurements reported in the present study.

5. Discussion

The main findings of the study reported here were: (1) the normal ranges (95% CIs) of the dorsal AFH coverage (width and area index) were 55–57% and 59–61%, respectively; (2) the normal range (95% CI) of Centre-edge angle was 27–29°, and values below 27° may be consistent with joint incongruence. Measures utilized to assess lateral AFH coverage (Norberg and Centre-edge angles) did not correlate with those utilized to assess dorsal AFH coverage (width and area indices). Our study would therefore recommend quantifying both dorsal and lateral AFH coverage. The positive correlation ($r_s = 0.58$) between Norberg and Centre-edge angles would support using Centre-edge angle as an alternative procedure to quantify lateral AFH coverage without consideration of the contralateral side; (3) angle of inclination greater than 132° and lesser than 130° may be consistent with coxofemoral incongruence; and (4) the normal ranges (95% CIs) of the acetabular slope angle were 7.7–9.3°

Centre edge (CE) angle and Norberg angle (NA) measure the degree of lateral acetabular coverage of the FH. The mean NA of our enrolled coxofemoral joints in group A (109.9°) was relatively consistent with the mean of the same group; (group A, 108.54°-106.9°) reported by previous veterinary literatures [19, 23]. However, the mean CE-angle of the (group A) identified in the present study (28°) differed from that reported in the previous study (16.91°) [19]. This difference might be related to the improved approach adopted in our study to measure the CE-angle using the iliac axis rather than the longitudinal axis employed

in the previous work. On the other hand, the normal values of the Centre-edge angle identified in our study ($\geq 28^\circ$) were relatively consistent with that reported in human literatures (25°) despite the difference in the anatomy and biomechanics between human and dogs [21, 24]; This may indicate the feasibility of using the iliac axis on canine VD pelvic radiographs rather than a longitudinal axis, which may be impractical for dogs to perform radiographic measurements [10, 24]. Positive correlation ($r_s = 0.58$) identified between NA and CE-angle in our study suggest the use of the modified CE-angle instead of NA to evaluate lateral AFH coverage of each joint separately without consideration of the contralateral hip joint . In the present study, a strong positive correlation ($r_s = 0.86$) was determined between the width and area indices that were calculated to assess the degree of dorsal AFH coverage. A relatively similar correlation ($r_s = 0.84$) was reported in a previous veterinary study [8]. The mean dorsal AFH coverage area index reported in our tested (group A) (56%) was relatively consistent with the mean that reported by Tomlinson and colleagues in 2000 (59.4%) [23]. The lack of correlation between the radiographic measures used to quantify lateral versus dorsal AFH coverage may support the authors' recommendation of considering both assessments to evaluate the overall AFH coverage during screening of canine hip joint .

The mean acetabular slope angle (AS-angle) measured in our study (8.5°) was less than that (17.5°) reported by Ajadi and colleagues [20]. This variation may be again related to the modification of the measurement technique that applied in our study via using iliac axis. The negative correlation ($r_s = -0.48$, $P < 0.0001$) between AS-angle and CE-angle implies a strong lateral AFH coverage with a low steep acetabular roof. The mean inclination angle of our enrolled normal coxofemoral joints (130.9°) is consistent with the values (129.4°) previously reported in normal

large breed dogs [14, 15]. The lack of correlation between our reported IA and all other radiographic parameters may be attributed to the normal joints investigated in the present study (lack of dysplastic joints). Thus, in dogs with hip dysplasia or secondary coxarthrosis due to accompanying joint incongruence, an aberrant IA is likely to alter the degree of AFH coverage.

Limitations

The absence of joint laxity assessment via distraction index calculation (PennHip DI) may limit the efficacy of radiographic evaluation of acetabular FH coverage in our proposed selective screening protocol, as joint laxity assessment would exclude additional dysplastic individuals from the breeding pool [25].

6. Conclusion

Dorsal AFH coverage width or area index less than 55% or 59%, respectively, would suggest lack of optimum dorsal coverage and possible subluxation. Norberg or Centre-edge angle below 109° or 27° , respectively, would suggest lack of optimum lateral acetabular FH coverage. The weak correlations identified between the measures of dorsal and lateral acetabular FH coverage would recommend considering both techniques to evaluate the overall FH acetabular coverage during screening protocol. Centre-edge angle could be utilized as alternatives to Norberg angle to quantify lateral acetabular FH coverage of each joint separately. Negative correlation between AS-angle and CE-angle suggests the relative consistency between a low steep acetabular roof and a high lateral AFH coverage. Normal coxofemoral joints exhibit IA between 130° - 132°

7. References

1. Rocha, B. D., Tôrres, R. C. S. (2007): Ultrasonic and radiographic

- study of laxity in hip joints of young dogs. *Arq Bras Med Vet Zootec.* 59: 90–6.
2. Demko, J., McLaughlin, R. (2005): Developmental Orthopedic Disease. *Vet Clin North Am Small Anim Pract.* 35: 1111–35.
 3. Skurková, L., Ledecký, V. (2009): Early diagnosis of canine hip dysplasia. *Folia Vet.* 53: 77–82.
 4. Simeonova, G. (2007): Hormonal and radiographic studies in German shepherd dogs with hip dysplasia. *Trakia J of Sciences.* 5: 59–64.
 5. Kimeli, P., Mbugua, S.W., Cap, R.M., Kirui, G., Abuom, T. O., Mwangi, W.E., et al. (2015): A retrospective study on findings of canine hip dysplasia screening in Kenya. *Vet World.* 8: 1326–30.
 6. Corral, C. (2018): Canine hip dysplasia: aetiology and treatment. *The Veterinary Nurse.* 9: 246–50.
 7. Butler, J. R., Gambino, J. (2017): Canine Hip Dysplasia Diagnostic Imaging. *Vet Clin Small Anim.* 47: 777–93.
 8. Janssens, L., Ridder, M. D., Verhoeven, G., Gielen, I., Bree, H. V. (2014): Comparing Norberg angle, linear femoral overlap and surface femoral overlap in radiographic assessment of the canine hip joint. *J Small Anim Pract.* 55: 135–38.
 9. Mostafa, A. A., Drüen, S., Nolte, I., Wefstaedt, P. (2012): Radiographic evaluation of early periprosthetic femoral bone remodelling and prosthetic stem alignment after uncemented and cemented total hip prosthesis in dogs. *Vet Surg.* 41: 69–77.
 10. Mostafa, A. A., Lucas, K., Nolte, I., Wefstaedt, P. (2016): Radiographic evaluation of early periprosthetic acetabular bone contrast and prosthetic head acetabular coverage after uncemented and cemented total hip prosthesis in dogs. *BMC Vet Res.* 12: 271–79.
 11. Coopman, F., Comhaire, F. H., Schoonjans, F. & De Brabander, K. (2006): Hip dysplasia research at Ghent University; towards a new approach to assess hip quality? Poster Presentation at the 9th Annual Canine Medicine Symposium, Davis, CA.
 12. Pereira, F., Giles, A., Wood, G. and Board, T. N. (2014): Recognition of minor adult hip dysplasia: which anatomical indices are important? *Hip Int.* 24: 175-179.
 13. Sarieler, M. (2004): Comparizon of femoral head inclination angle measurement in dysplastic and non-dysplastic dogs of different breeds. *Acta Veterinaria Hungarica.* 52 (2), pp. 245–252.
 14. Hauptman, J., Cardinet, III. G. H., Morgan, J. P., Guffy, M., Wallace, L. J. (1985): Angles of inclination and anteversion in hip dysplasia in the dog. *Am J Vet Res.* 46: 2033–6.
 15. Hauptman, J., Prieur, W. D., Butler, H. C., Guffy, M. M. (1979): The angle of inclination of the canine femoral head and neck. *Vet Surg.* 8: 74–7.
 16. Rendano, V. T., Ryan, G. (1985): Canine hip dysplasia evaluation. *Vet Radiol.* 26: 170–86.
 17. Mostafa, A. A. et al. (2018): Influence of radiographic techniques on the measurement of femoral anteversion angles and a conformation score of pelvic limbs in Labrador retrievers. *Vet Surg.* 47: 421–30.
 18. Brass, W., Paatsama, S. (1983): Hip dysplasia - International certificate

- and evaluation of radiographs. Scientific Committee, Fédération Cynologique Internationale (FCI), Helsinki, Finland. Mimeograph, p25.
19. Meomartino, L., Fatone, G., Potena, A., Brunetti, A. (2002): Morphometric assessment of the canine hip joint using the dorsal acetabular rim view and the Centre-edge angle. *J Small Anim Pract.* 43: 2–6.
 20. Ajadi, R. A., Sanni, J. L., Sobayo, E. L. (2018): Evaluation of radiographic coxofemoral measurements in Boerboel dogs. *Folia Vet.* 62: 66–73.
 21. Wiberg, G., Lund, M. D. (1953): Shelf operation in congenital dysplasia of the acetabulum and in subluxation and dislocation of the hip. *J Bone Joint Surg Am.* 35: 65–80.
 22. Fa, L., Wang, Q., Ma, X. (2014): Superiority of the modified Tönnis angle over the Tönnis angle in the radiographic diagnosis of acetabular dysplasia. *Exp Ther Med.* 8: 1934–8.
 23. Tomlinson, J. L., Johnson, J. C. (2000): Quantification of measurement of femoral head coverage and Norberg angles within and among four breeds of dogs. *American Journal of Veterinary Research.* 61, 1492-1500.
 24. Fredensborg, N. (1976): The results of early treatment of congenital dislocation of the hip. *J Bone Joint Surg Br.* 124: 18–28.
 25. Gaspar, A. R., Hayes, G., Ginja, C., Ginja, M. M., Todhunter, R. J. (2016): The Norberg angle is not an accurate predictor of canine hip conformation based on the distraction index and the dorsolateral subluxation score. *Prev Vet Med.* 135: 47–52.

Table 1: The mean (\pm SD) values and 95% confidence intervals for radiographic measurements quantifying lateral acetabular femoral head coverage (Norberg and Centre-edge angles), dorsal acetabular femoral head coverage (width and area indices), steepness of cranial acetabular edge (acetabular index angle), and the (inclination angle) for Labrador retrievers with normal coxofemoral joints.

	Normal coxofemoral joints (n = 111)	
Variable	95% CI	Mean \pm SD
Norberg angle (degree)	109.3 - 110.5	109.9 \pm 3.2
Centre-edge angle (degree)	27.3 - 28.7	28.0 \pm 3.8
Dorsal acetabular femoral head coverage width (mm)	11.9 - 12.5	12.2 \pm 1.7
Femoral head diameter (mm)	21.3 - 22.1	21.7 \pm 2.3
Dorsal acetabular femoral head coverage width index	0.55 - 0.57	0.56 \pm 0.06
Dorsal acetabular femoral head coverage area (mm ²)	216.2 - 234.5	225.4 \pm 48.3
Femoral head area (mm ²)	359.9 - 388.5	374.2 \pm 75.4
Dorsal acetabular femoral head coverage area index	0.59 - 0.61	0.60 \pm 0.05
Acetabular index/slope angle (degree)	7.7 - 9.3	8.5 \pm 4.2
Inclination angle (degree)	129.8 - 132.2	131.0 \pm 6.2

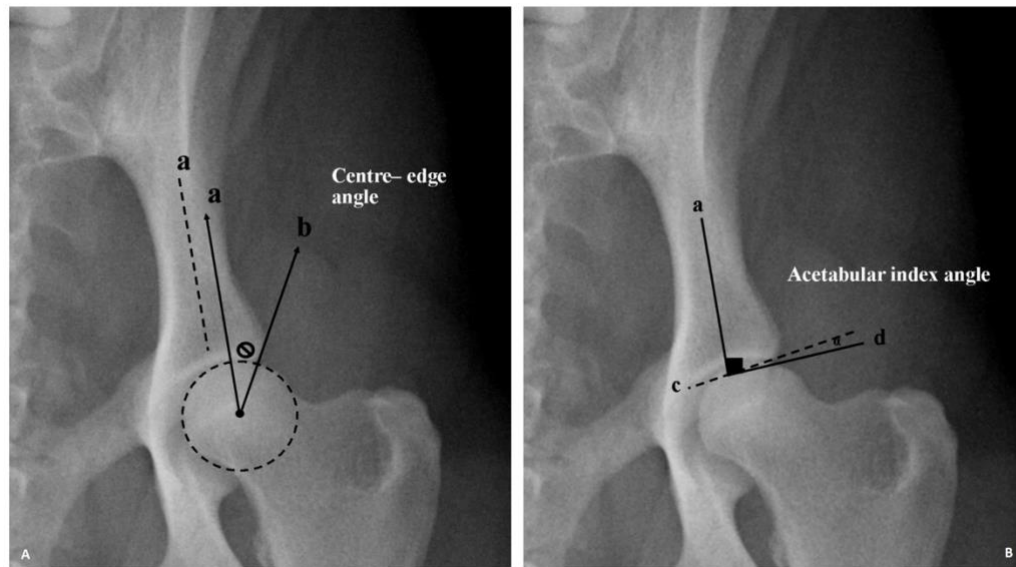


Fig .1. Ventrodorsal pelvic radiograph of a normal coxofemoral joint illustrating measurements of Centre-edge angle (Φ) (A) and acetabular index/slope angle (α) (B). a, long axis of the iliac body; b, a line originating from the femoral head center and tangential to lateral acetabular rim; c, a line tangential to lateral and medial extents of the cranial acetabular rim (acetabular sourcil); d, a horizontal line perpendicular to the iliac axis (a).

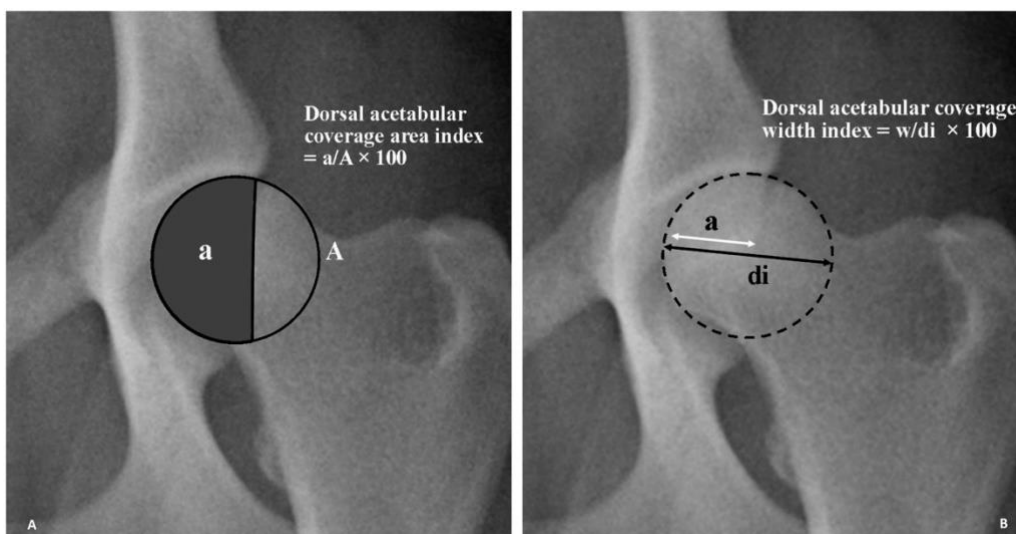


Fig .2. Ventrodorsal pelvic radiograph of a normal coxofemoral joint illustrating measurements of dorsal acetabular femoral head coverage area index (A) and dorsal acetabular coverage width index (B). w, width of dorsal acetabular coverage; di, diameter of the femoral head; a, area of dorsal acetabular coverage; A, area of the femoral head.

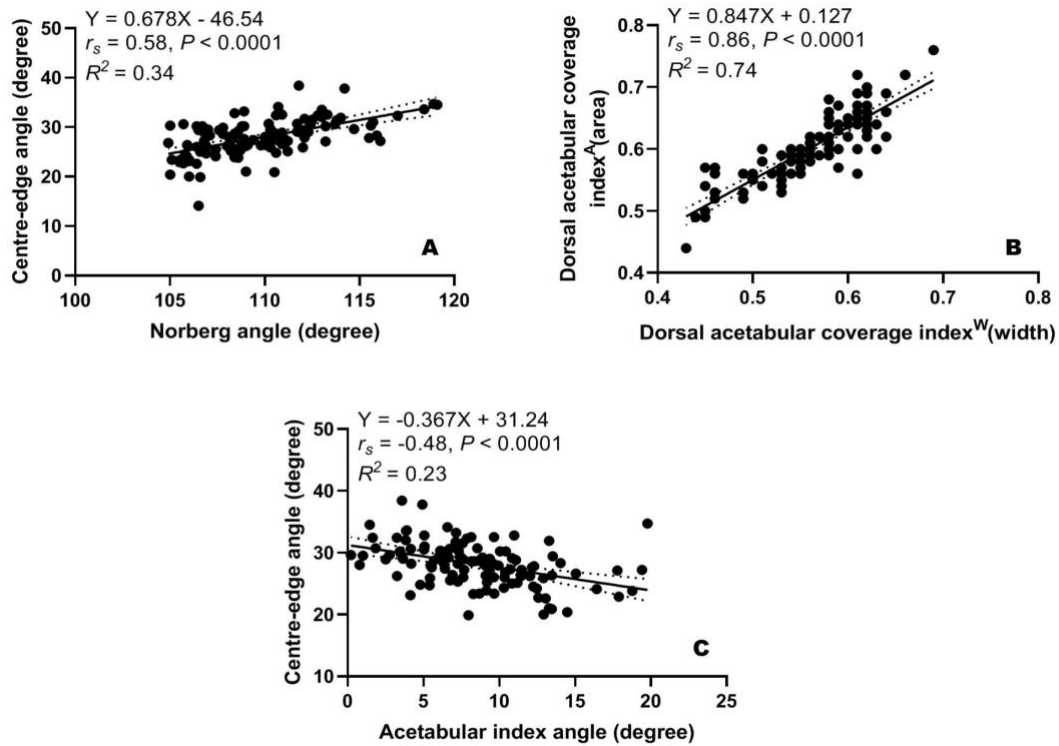


Fig .3. Scatterplots of Centre-edge angle versus Norberg angle (A), dorsal acetabular coverage area index versus dorsal acetabular coverage width index (B), and of acetabular index angle versus Centre-edge angle (E) determined for 111 normal coxofemoral joints of 72 Labrador Retrievers.